

# JOURNAL of FORENSIC ODONTO- STOMATOLOGY

## VOLUME 34 Number 1 July 2016

### SECTION IDENTIFICATION

## The Use of Intraoral Radiographs for Identification of Edentulous Patients Rehabilitated With Implants

Johan Johansson<sup>1</sup>, Magnus Bladh<sup>1</sup>, Mats Sjöström<sup>2</sup>, Jan Ahlqvist<sup>3</sup>

<sup>1</sup>Department of Odontology, Faculty of Medicine, Umeå University, Umeå, Sweden.

<sup>2</sup>Oral and Maxillofacial Surgery, Department of Odontology, Faculty of Medicine, Umeå University, Umeå, Sweden.

<sup>3</sup>Oral and Maxillofacial Radiology, Department of Odontology, Faculty of Medicine, Umeå University, Umeå, Sweden.

Corresponding author: Jan.Ahlqvist@umu.se

The authors declare to have no conflict of interest.

### ABSTRACT

*The aims of this study were; i) to determine the accuracy by which two intra-oral radiographic examinations performed on patients with edentulous mandibles treated with dental implants can be matched. ii) to determine whether prosthodontic supra-construction is important for matching. iii) to investigate whether there is a difference between oral and maxilla-facial radiologists (OMR) and dental practitioners, not specialized in oral and maxillofacial radiology (NOMR), regarding their ability to match.*

*The specific features of the radiographs used by the operators to acquire a match were also investigated.*

*Intra-oral radiographic examinations from 59 patients were utilized. Radiographic examinations from 47 patients carried out at placement of the supra-construction and at subsequent follow-up examinations were used as “ante-mortem” and “post-mortem” records respectively. Examinations from 12 patients were added to the “post-mortem” records without “ante-mortem” records being available.*

*The study was divided into two parts. In Part One all “ante”- and “post-mortem” records had the supra-construction masked and in Part Two it was visible. Seven dentists (4 OMR, 3 NOMR) were instructed to specify on what basis each matching was made on the confidence of a three-graded scale*

*OMR had 93.2 % and 98.5 % accuracy in Parts One and Two respectively. NOMR had 63.8 % and 87.9 %. Bone anatomy was the most commonly used feature by OMR to obtain a match. For NOMR it was the appearance of the fixtures. OMR reported higher confidence in their ability to match the examinations. This study indicates that OMR could be a valuable resource in cases of identification where dental implants are a feature of the post-mortem dental records.*

**KEYWORDS:** dental identification, forensic odontology, dental implants, intra-oral radiographs, edentulous patients

## INTRODUCTION

The mother of Emperor Nero, Agrippina (15-59 A.D.), was able to identify a murdered rival, Lollina Paulina, due to the victim's characteristic dental arch. To this day, this is the first documented case of dental identification.<sup>1</sup>

Almost two thousand years later, in 1965, Per-Ingvar Brånemark (1929-2014) incorporated the first dental implant in a human patient.<sup>2</sup>

Today, dental implants are widely used in rehabilitation for edentulousness and there are more than 460 different implant systems available worldwide,<sup>3</sup> with the *ad modum* Brånemark procedure being the most common implant technique in Sweden.<sup>2</sup>

Due to the increasing number of people rehabilitated with oral implants, it is inevitable that any future human disaster will contain human remains with oral implants to be a feature of the recovered jaws. Despite the increasing popularity of oral implant treatments few studies have investigated the accuracy of establishing person-identity based on intra-oral radiographs of edentulous jaws treated with implants.

In a study by Borrman *et al*, the question was raised whether the accuracy in establishing the identity of persons by intra-oral radiographs was dependent on

the observer's field and degree of specialisation in dentistry.<sup>4</sup> In later studies it was concluded that dentist's specialized in oral and maxillofacial radiology had a higher accuracy rate than general practitioners or dentists specialized in other fields.<sup>5-7</sup>

The aims of this study were; *i*) to determine the accuracy by which two intra-oral radiographic examinations taken on separate occasions on patients with edentulous mandibles treated with dental implants could be matched. *ii*) To determine to what extent prosthodontic supra-construction used in implant treatment was of importance in the identification process. *iii*) To determine whether there was a difference between oral and maxillofacial radiologists and dental practitioners not specialized in oral and maxillofacial radiology regarding their ability to match the radiographic examinations.

Because of the lack of dental status in these edentulous cases where only morphological differences and the implant features were used to base the interpretation, it is of interest to know which features the operators used to make their matches. Against this background the study also investigated those features of the intra-oral radiographs that operators most commonly used in making a match.

## MATERIALS AND METHODS

The study material was collected from the implant archives at the department of Oral and Maxillofacial Surgery at the University

hospital of Umeå (Norrlands universitetssjukhus, NUS), Sweden. Inclusion criteria comprised two intra-oral radiographic examinations taken on separate occasions of patients with edentulous mandibles treated with four implants of Nobel Biocare Brånemark system 3.75 mm. Study material from 59 patients (29 males and 30 females) fulfilled the inclusion criteria.

The radiographic examinations were carried out by different examiners using different X-ray machines. Thus the study material simulated a potential real-life scenario where radiographs taken ante-mortem for placement of implants were compared to radiographs taken post-mortem from a location where decedants were discovered of unknown identity. The mean age of the patients was of 73 years (ranging between 32 and 96 years). All of the intra-oral radiographs were anonymized. The study was performed in accordance with the principles of Helsinki Declaration.

Two intra-oral radiographic examinations performed on different occasions from each of 47 patients (23 males and 24 females) served to simulate “ante-mortem” and “post-mortem” material respectively. The radiographic examinations available at placement of the supra-structure were used as “ante-mortem” records and subsequent follow up radiographic examinations taken some time following placement of the supra-structure served as “post-mortem” records. Each radiographic examination comprised up to eight intraoral radiographs.

All four implants were visible in the “ante-mortem” records. Some implants had

failed following placement and, as a result, the number of implants demonstrated in the “post-mortem” records varied between two and four. Intraoral radiographic examinations of the remaining 12 patients were added to create a difference in number between the number of “post-mortem victims” and the number of “ante-mortem missing persons” in an attempt to add further rigour to the study. Each “ante-mortem” record was assigned a two-digit number and gender. The “post-mortem” records were each assigned gender and a randomized three-digit number.

The examinations were compiled in two Microsoft PowerPoint presentations (Microsoft PowerPoint 2010, Microsoft Corporation, Redmond, WA, USA), one presenting “ante-mortem” examinations and the other presenting “post-mortem” examinations. The two presentations were installed on a computer in a dedicated observation room at the Department of Oral and maxillofacial radiology of NUS. The two presentations could be studied simultaneously and the participants could freely scroll through the records and zoom in and out each radiograph according to their preference. A printed version of all records was also available in the observation room. Three participants were unable avail themselves of the facility of the dedicated observation room and were given the PowerPoint presentations on USB drives for interpretation on their own computers.

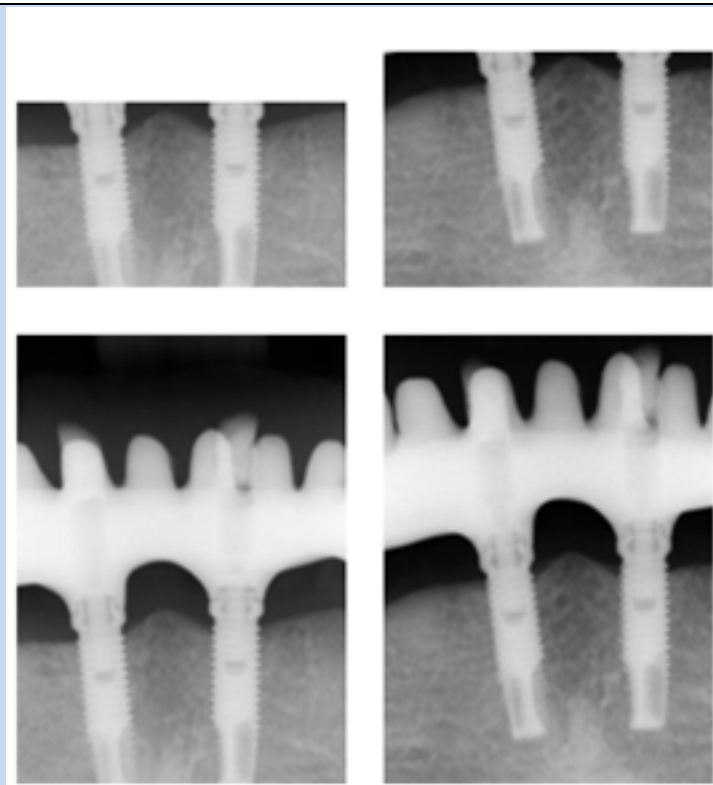
Four oral and maxillofacial radiologists (OMR) and four dentists not specialized in oral and maxillofacial radiology (NOMR) were invited to participate in the study. Each participant received written instructions about the study and an answer form in which they were asked to individually link each “ante-mortem” record to a matching “post-mortem” record. They were also informed that there

were twelve “post-mortem” records with no corresponding “ante-mortem” records.

The participants were instructed to specify on what basis each matching was made; anatomy, fixture, supra-construction (Part Two), or other observation and to grade the confidence of every match on a three-graded scale: “certain”, “probable” and “possible”.

The study was divided into two parts. In Part One all “ante” and “post-mortem” records had the supra-construction masked

The masking was performed in Microsoft PowerPoint using built in drawing tools and ready-made shapes; the criterion was that no part of the supra-construction should be visible, thus the bottom of the masking border was placed in the abutment region of each implant (Fig. 1). In part two, the supra-constructions were visible. This was done to investigate whether the supra-construction is of significance in the identification process. Part Two was carried out following completion of Part one. The same set of records was used both times.



**Fig.1:** Example of radiographs of the same patient and region from different dates. Upper row; when the supra-construction was masked (Part One). Lower row; when the supra-construction was visible (Part Two). Upper left: masked “ante-mortem”. Upper right: masked “post-mortem”. Lower left: unmasked “ante-mortem”. Lower right: unmasked “post-mortem”

The numbers of correct matches were registered and the results compared using non-parametric tests (Fisher’s exact test, McNemar’s test). A positive match was considered correct irrespective of graded confidence level. A blank answer was counted as an erroneous match. The level of significance was set at 5 %.

## RESULTS

One participant from the NOMR group did not submit any answer form. In total 3 participants from the NOMR group and 4 participants from the OMR group completed the study.

Out of 47 possible matches the average number of correct matches in Part One was 43.8 for OMR and 30.0 for NOMR. The difference between the groups was statistically significant ( $p = 0,001$ ) (Table 1). One participant from the OMR group did not submit matches for all 47 cases but left 12 cases blank. All other participants submitted complete answer forms.

In Part Two, the average number of correct matches was 46.3 for OMR and 41.3 for NOMR group. The difference was not statistically significant ( $p = 0,111$ ). Both groups had a higher accuracy in part two, and the increase in accuracy was statistically significant for both groups.

The largest increase in accuracy was seen in the NOMR group (Table 1).

The feature most commonly used for identification in Part One differed between the OMR and NOMR groups. On average,

% of the cases. Instead of utilizing the bone anatomy most of the NOMR group used the appearance of the fixture as an

Table 1 - Number of correctly matched cases (mean, min and max) in the group of Oral and Maxillofacial Radiologists (OMR) and the group of dental practitioners (NOMR) when the supra- structure was masked (Part One) and visible (Part Two) respectively

Category	Number of correctly matched cases out of 47 (mean, max, min)	%	P-value
Part One			
OMR	43.8, (35, 47)	93.2 %	0.001 <sup>1</sup>
NOMR	30.0, (21, 38)	63.8 %	
Part Two			
OMR	46.3, (45, 47)	98.5 %	0.111 <sup>1</sup>
NOMR	41.3, (38, 45)	87.9 %	
Difference Part One vs. Part Two			
OMR		+ 5.7 %	<0.001 <sup>2</sup>
NOMR		+ 37.8 %	
<sup>1</sup> Fisher's exact test <sup>2</sup> McNemar's test			

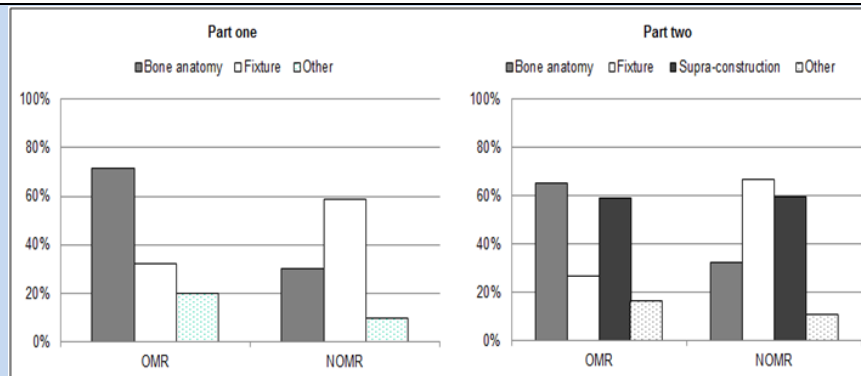
the OMR group most often utilized the bone anatomy as an identification marker (72 % of the cases) whereas the NOMR group utilized the same feature in only 30

identification marker (59 %).

In Part Two, the features most commonly used for identification in the OMR group

were, firstly, information relating to bone anatomy (65 %) and, secondly, the design of the supra-construction (59 %). The features most commonly used for

identification in the NOMR group were, firstly, information about the fixtures (67 %) and, secondly, the design of the supra-construction (60 %) (Fig. 2).

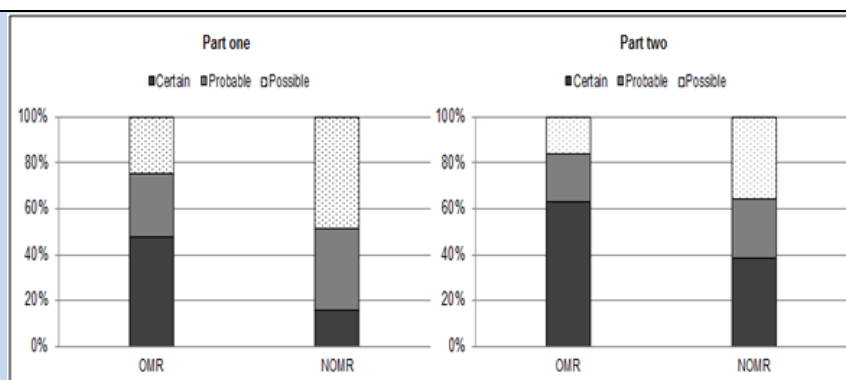


**Fig. 2:** The proportion of cases in which different features (*i.e.* bone anatomy, fixture, and supra-construction) were used by Oral and Maxillofacial Radiologists (OMR) and dental practitioners (NOMR) when matching cases. Part One; when the supra-construction was masked. Part Two; when the supra-construction was visible

For the feature category named “other”, participants reported characteristics such as foreign bodies, gut-feeling and decisions made by elimination method (Fig. 2).

In both Parts One and Parts Two, on average, OMR more frequently graded their matches with certainty than did

NOMR. Both groups reported an increased certainty in Part Two. The largest average increase in certainty from Part One to Part Two was seen in the NOMR-group (Fig. 3). All cases reported as “identified with certainty” were correct, except for one assessment in Part One and two assessments in Part Two all submitted by the NOMR group.



**Fig. 3:** Proportion of matched cases reported as certain, probable and possible by Oral and Maxillofacial Radiologists (OMR) and dental practitioners (NOMR). Part One; when the supra-construction was masked. Part Two; when the supra-construction was visible

## DISCUSSION

The findings of this study suggest that it is possible to match intra-oral radiographs



taken on different occasions of edentulous mandibles treated with the same implant system. Access to information about the supra-construction increases accuracy and confidence but is not, according to our findings, essential in order to obtain correct matches.

Dentists specialized in oral and maxillofacial radiology were superior to dentists not specialized in oral and maxillofacial radiology. In both parts of the study the OMR group showed a higher mean total number of correctly matched cases compared to the NOMR group. In Part One the difference was statistically significant.

An interesting finding was that the OMR group more often utilized the anatomy of bone as an identification marker than did the NOMR group. This was a consistent finding throughout both parts of the study and could indicate that radiologists are more familiar with using and interpreting a wide spectrum of landmarks in intra-oral radiographs. This has previously been discussed by Borrman *et al.*<sup>4,7</sup>

In Part Two, in the majority of cases, both groups utilized information about the supra-constructions in the identification process, but as described above, the two groups differed in how they collated the information with other features.

The largest increase in accuracy from Part One to Part Two was seen in the NOMR group. This could imply that information about the supra-construction is of greater importance for those with less

radiographic experience than it is for dentists specialized in oral and maxillofacial radiology. The participants in the OMR group used bone anatomy, unique for each individual, in the majority of cases as a basis for their matching. This means that that, for the OMR group, important information in the material was present in both parts of the study and could explain the similar results achieved for each of the two parts. Another explanation could be that the OMR group already had a high accuracy in part one, making a large increase in improbable.

Apart from the fact that the participants in the NOMR group achieved a lower success rate in matching the examinations than the OMR group, they were also less confident when matching the cases. It may be assumed that they the NOMR group were uncomfortable and inexperienced in these circumstances. An earlier study has discussed the difficulty of studying oral radiographs in jaws treated with oral implants.<sup>8</sup>

Both groups reported increased confidence in Part Two, suggesting that the visible supra-constructions was an aid in the decision making process. NOMR showed the largest increase in confidence from Part One to Part Two. This might strengthen the idea that information about the supra-construction is of greater importance for dentist with less experience in radiology.

In this study the participants had no information about the time of date for each radiograph. Such information could be of



use in the identification process, for instance, to evaluate bone loss and other alterations over time. Therefore it would be desirable to present such information in future studies.

Many of the intra-oral radiographs used in this study were of different brightness and contrast and this fact may have complicated interpretation. Future studies should consider the use of radiographic viewing programmes designed with an option for participants to alter brightness and contrast settings according to preference.

In reality, and in a variety of circumstances when victim identification becomes paramount, it is often possible to take supplementary "post-mortem" radiographs to better depict the area of interest and to "mimic" more closely the settings and projections of the ante-mortem images.<sup>2</sup> The ethical considerations of this study based on living patients precluded this possibility but, nonetheless, it is plausible to believe that the participants would have obtained an even higher accuracy should this option have been available.

## CONCLUSION

This study show that it is possible to correctly match radiographic intra-oral examinations performed on different occasions of edentulous mandibles treated with oral-implants and that dentists specialized in oral and maxillofacial radiology do so with higher accuracy than dentists not specialized in oral and maxillofacial radiology.

This suggests that oral and maxillofacial radiologists could potentially be a valuable resource in future identification occasions where dental implants were a feature of the post-mortem dental records. Due to the increasing number of people rehabilitated with oral implants, it is inevitable that any future human disaster identification process will contain human remains where oral implants are a feature of the recovered jaws.


## ACKNOWLEDGEMENT

We wish to thank the oral and maxillofacial radiologists and dental practitioners who participated in the study. Your contributions made this study possible.

## REFERENCES

1. Sansare K. Forensic odontology, historical perspective. *Indian J Dent Res.* 1995 Apr-Jun;6(2):55-7.
2. Korkchi M, Lekholm U, Dahlbom U, Borrman H. Accuracy in identification of implant treated patients by use of intraoral radiographs. *J Forensic Odontostomatol.* 1995 Jun;13(1):4-8.
3. Berketa JW, James H, Langlois NE, Richards LC. A study of osseointegrated dental implants following cremation. *Aust Dent J.* 2014 Jun;59(2):149-55.
4. Borrman H, Gröndahl HG. Accuracy in establishing identity by means of intraoral radiographs. *J Forensic Odontostomatol.* 1990 Dec;8(2):31-6.
5. James H. Thai tsunami victim identification overview to date. *J Forensic Odontostomatol.* 2005 Jun;23(1):1-18.
6. Fridell S, Ahlqvist J. The use of dental radiographs for identification of children with unrestored dentitions. *J Forensic Odontostomatol.* 2006 Dec; 24(2):42-6.





**The Use of Intraoral Radiographs for Identification of Edentulous Patients Rehabilitated With Implants.** *Johansson et al*

7. Borrmann H, Gröndahl HG. Accuracy in establishing identity in edentulous individuals by means of intraoral radiographs. *J Forensic Odontostomatol.* 1992 Jun;10(1):1-6.
8. Bóscolo FN, Almeida SM, Haiter Neto F, Oliveira AE, Tuji FM. Fraudulent use of radiographic images. *J Forensic Odontostomatol.* 2002 Dec;20(2):25-30.

\*\*\*\*\*