



JOURNAL of FORENSIC ODONTO-STOMATOLOGY

VOLUME 32 Number 1 July 2014

SECTION BITE MARKS

Are they dermatological lesions, bottle top burns or bite mark injuries?

Jayanie B. Weeratna¹

¹ Forensic Odontologist, Institute of Legal Medicine and Toxicology, Colombo, Sri Lanka

Corresponding author: jayanie.weeratna@gmail.com

The author declares to have no conflict of interest.

ABSTRACT

Bite marks can be considered as a patterned injury where identification of the causative tool will lead to the identification of the perpetrator. When patterned injuries resembling bite marks are seen on the victim or an assailant of a potential crime, all efforts must be made to carry out an immediate and proper investigation.

The classical human bite mark pattern will appear as an oval or circular injury. However there are several dermatological lesions which can be misinterpreted or confused with bite marks. Similarly scars left as a result of contact with hot objects can sometimes bear a resemblance to bite marks. To the untrained eye, identification of bite mark injuries is not an easy task.

Since bite marks are common in cases of child abuse and neglect, it is recommended that dental surgeons with forensic background become members of the child abuse and neglect management teams.

During investigation of bite marks in alleged cases of child abuse and neglect, it is imperative to compare the injury with dentition of all the persons who have direct access to the child including siblings and playmates. Information revealed through the forensic analysis of bite marks not only helps in the criminal investigation but also in the clinical management of the persons concern

KEYWORDS: Forensic odontology, Bite marks, Child abuse and neglect, Siblings and play mates, Dermatological lesions, Bottle top burns

INTRODUCTION

Bite mark evidence is now accepted within many jurisdictions.¹ If a mark contains sufficient detail and data it can be used to identify the perpetrator and /or exclude suspects thereby becoming a powerful tool in criminal investigations.²⁻⁴ Not all bite marks can be analyzed and presented as evidence in court of law.

Teeth can be used as weapons and as a result, bite marks are usually seen in crimes against persons and such injuries are referred to as attack injuries.⁵ They are frequently found on victims of homicide, domestic violence, sexual abuse and child abuse cases.^{4,6} Bite marks are also found on children who have been involved in fights with same-age children and also among institutionalized individuals.⁷ It is not uncommon to find bite marks on perpetrators of violence which are usually known as defense injuries.⁵

A classical human bite mark will appear with specific markings as a circular or oval shaped injury⁸ but they also can mimic burn injuries, bottle top injuries⁹ and dermatological lesions⁷ and vice-versa.

It is important that healthcare workers are adequately aware of such injuries so that pertinent cases are referred to the relevant specialists in forensic odontology for further investigations and differential diagnosis. This will especially help in early detection and facilitate initiating proper therapy and counseling as well as a search for the perpetrator where indicated.⁷ All dentists and dental hygienists should be familiar with the clinical appearance of bite marks because it may be the first sign of child abuse and child neglect.^{4,7}

This case report describes a case where marks on the skin were clinically mistaken initially for dermatological lesions and subsequently as bottle top burn injuries before finally being recognized as bite marks which provided major evidence in investigations and clinical management.

CASE HISTORY

On 18th January 2013 a female child aged 3 years was referred to the Forensic Odontology Unit by a Consultant Judicial Medical Officer in the Institute of Legal Medicine and Toxicology, Colombo, Sri Lanka for forensic odontological examination. At the time of the examination she was in the care of a Consultant Pediatrician at the Lady Ridgeway Children's Hospital in Colombo, Sri Lanka. This child had been treated by two different medical officers prior to being admitted to the children's hospital for a condition which was suspected to be a dermatological condition. Since the child's response to the medical treatment was not satisfactory she was referred for specialist care in Colombo. When the said child was examined by the Pediatric Dermatologist, he suspected that the child was being subjected to physical trauma i.e. burnt with heated bottle tops. The child was then referred to the Consultant Pediatric Psychiatrist and subsequently to the Consultant Judicial Medical Officer to investigate the cause of the injuries.

The child was in the care of her parents. She was the youngest in a three-children family. Her siblings were an elder sister aged 11 years and an elder brother of 8 years. During the day the elder children attend school while the youngest stayed at home with the mother. The mother was the chief care giver in the family and was a housewife who suffered from diabetes mellitus with poor glycaemic control. According to the social worker's report the child was living in a well-functioning home but there were limitations of space allowing the youngest child easy access to the schoolbooks of the oldest child. Furthermore there were opportunities for the three children to play away from adult supervision. In these circumstances, access to the child was limited to the family members.

There were 42 separate injuries on the child which were in the areas of the face, upper limbs, front and back of the body (Fig. 1). No such injuries were found on the lower part of the torso (below

the waist) and on the lower limbs. The injuries were in different healing stages. The injuries were photographed after obtaining an informed proxy consent from the father. Biological swabs were not taken.

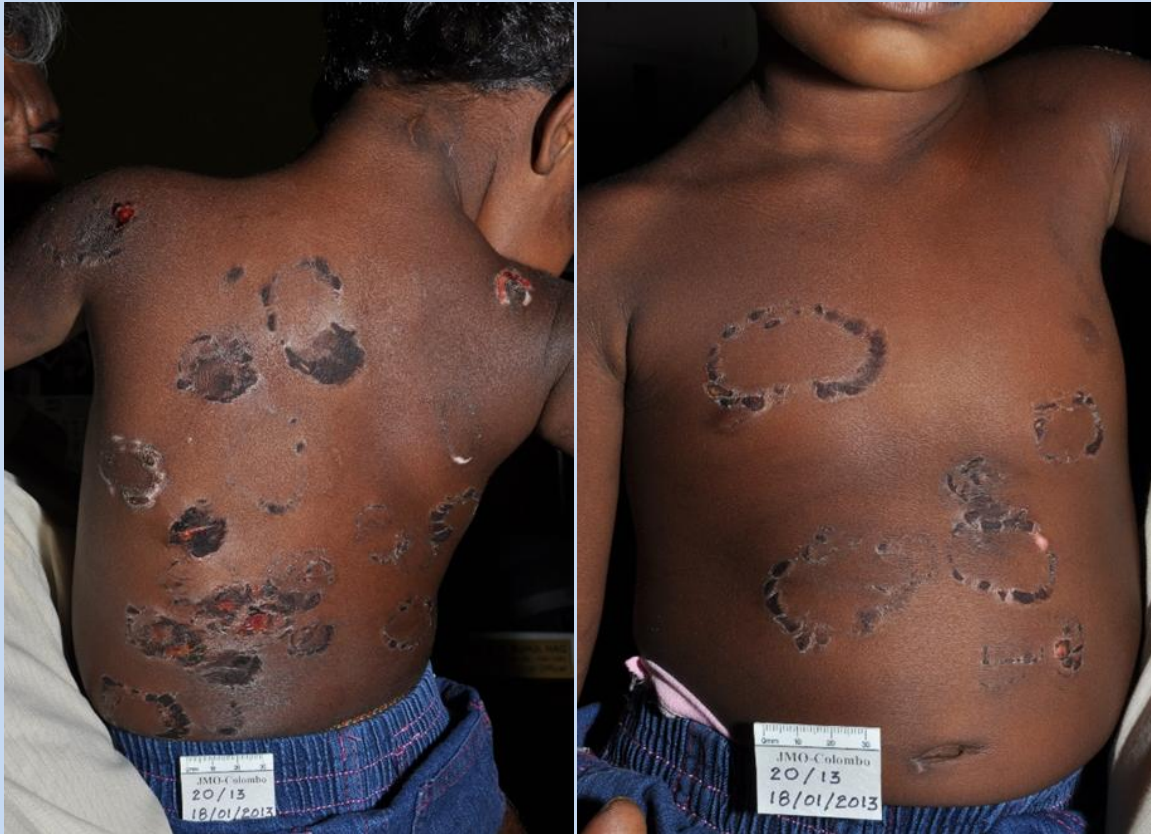

Fig.1: Back of the body(left); Front of the body (right)

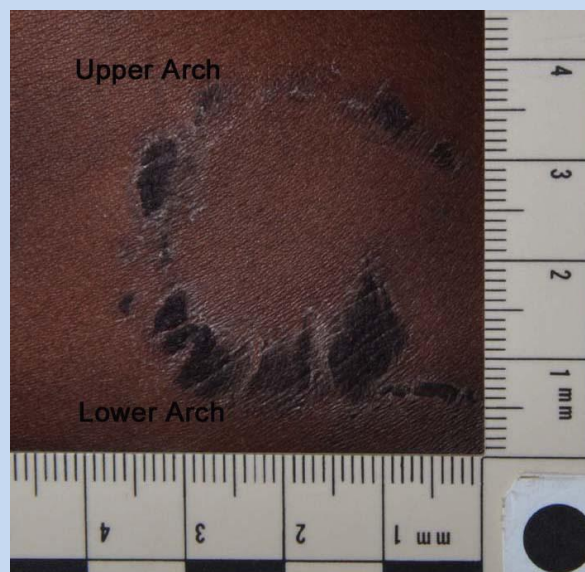
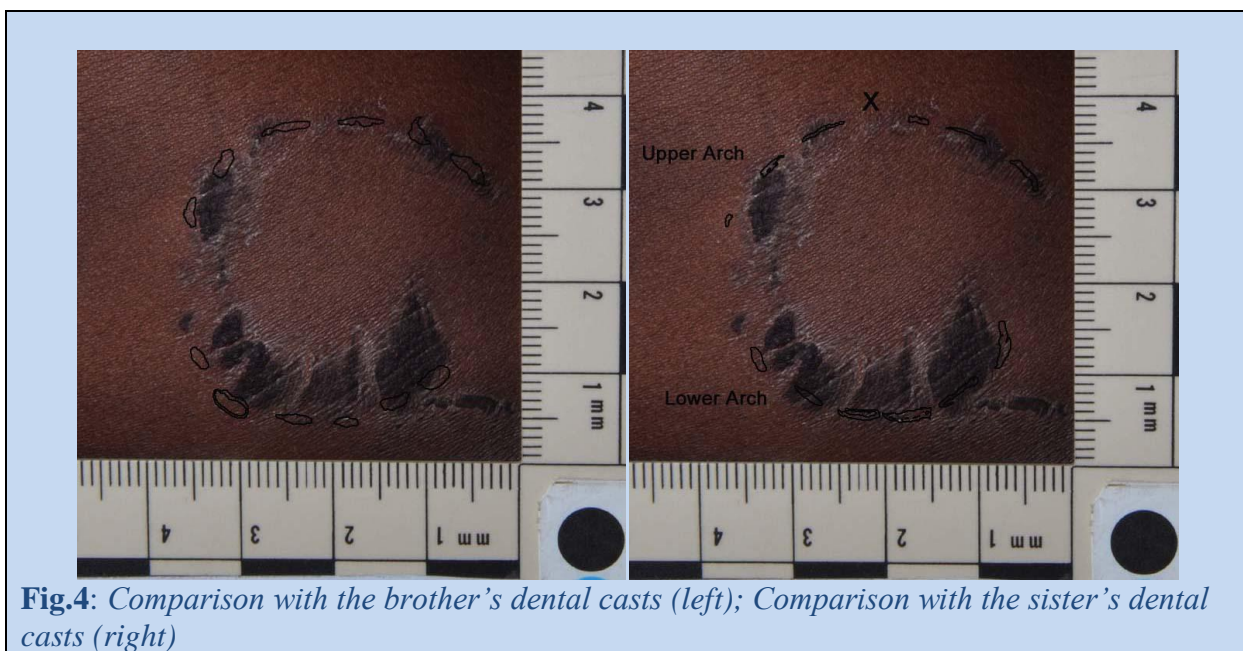
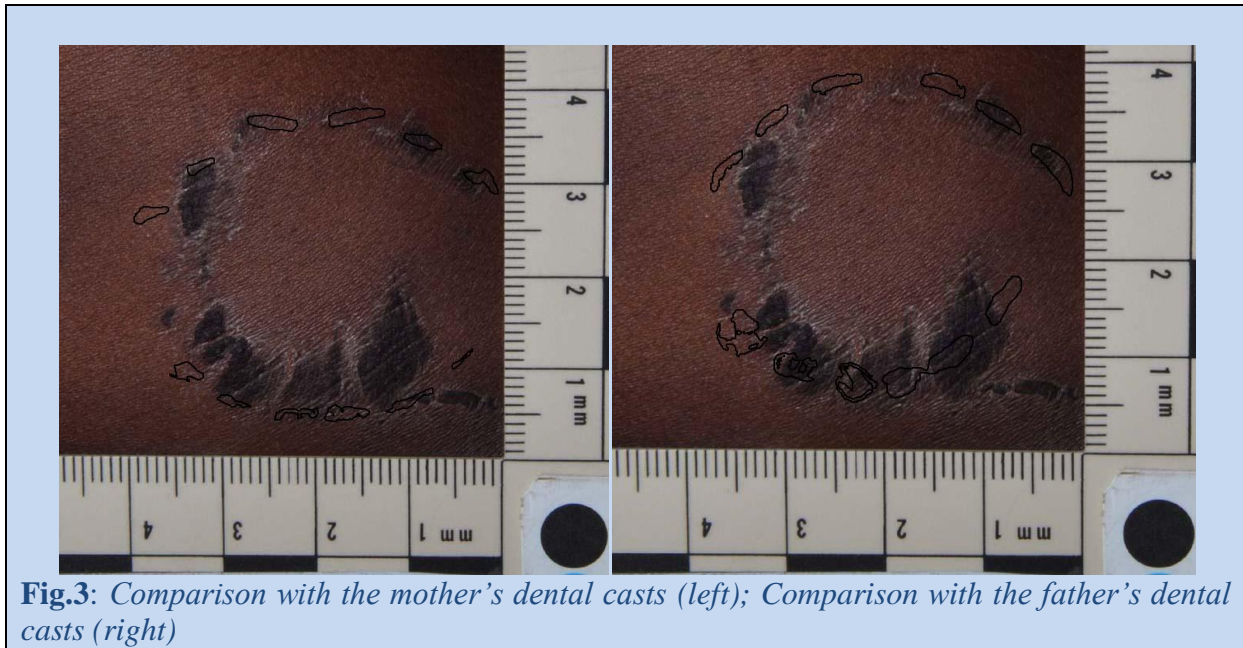


Fig. 2: Injury

A wax bite of the victim and alginate impressions of the dentition of all the family members were taken after obtaining voluntary informed consent from the parents and proxy consent for the children by the father. Subsequently Plaster of Paris (POP) study models were prepared. Digital overlays of all the dental casts were

produced using the technique described by Johansen and Bower.¹⁰ An injury which showed clear features (Fig.2) was selected for analysis and was photographed digitally and edited using the computer software Adobe Photoshop®. The digital overlays of all the family members were then compared with the photograph of the selected injury (Figs.3-4).



Since the people who had direct access to the child were known, for bite mark analysis, this case was considered to be a “closed population case”. The dental arch of the mother, father and the brother showed gross incompatibility with the shape of the injuries (Fig. 3-4). The arch and dental characteristics found in the sister’s dentition could be correlated to the features in the injury to a certain extent.

- Arch width, for both upper and lower casts of the sister, was consistent with the injury.
- The unevenness in the incisal edge of tooth 11 was present as a lightly injured area (marked X in Fig 4) in comparison to the rest of the areas in the injury.
- The lower central incisors have even biting surfaces (Fig. 5) with a very tight contact. This corresponds to the single indentation mark seen on the arch that was identified as the injury caused by the lower teeth.

The uneven incisal edge in the upper central incisors is a feature that is not uncommon in the Srilankan population and the frequency of the occurrence of this feature in the age group concerned is also unknown.

In the final analysis and assessment of the injury, it was concluded that:

- The injuries are a result of an ongoing process of human biting (positive bite marks).
- They are not a result of self-inflicted bites.
- It excludes the father, mother and the brother being the cause of the injuries.
- The pattern analysis of the injury is suggestive that a dentition similar to that of the sister has caused the injuries.
- The sister is the probable biter considering the fact that this is

- a closed population case scenario

Outcome of the investigations: Even though the evidence produced may not have been sufficient to prove a case in a court of law, having considered the extent of the injuries and circumstances around the case it was decided to convey the findings to the Consultant Judicial Medical officer by way of a confidential report and subsequently to the Pediatric Psychiatrist as it could help in medical management of the case.

On the recommendation of the Forensic Pathologist, the family was directed to a family counseling service and the elder sister subsequently confessed. She was then referred to the Pediatric Psychiatrist for necessary management. Under the recommendations of the social service officers the family moved into a better housing facility. After six months of treatment for the injuries by the dermatologist and counseling services to both the family and the elder sister, the child is now observed to be free of any further evidence of recent injuries of similar nature.

DISCUSSION

Recognition, recovery, analysis and interpretation of bite marks is one of the most challenging tasks that a forensic odontologist has to perform. With the advancements in technology, analysis of bite marks has now become more objective as well as highly technical.¹¹ Presenting the findings in a court of law and explaining the findings to the legal professionals and jurors can be difficult.¹² For a forensic odontologist to be competent in analysis of bite marks requires not only the knowledge/education but also skill and practice.¹³

Bite mark analysis is carried out in three stages. Firstly the evidence is recovered from the bite mark; secondly the details of the suspects’ dentitions are recorded and finally the pattern and individual details of

the mark are compared with the features of the suspects' dentitions. As a general rule the bite mark should be examined first and recorded before examining the suspects' dentitions to avoid any subliminal bias during the interpretation of the mark.¹⁴ This general principal was followed in the described case. The American Board of Forensic Odontology (ABFO)¹⁵ provides an array of terminology that can be used to describe whether or not an injury is a bite mark. These are:

1. *Human bite mark* – Human teeth created the pattern; other possibilities were considered and excluded
2. *Suggestive human bite mark* – The pattern is suggestive of a human bite mark, but there is insufficient evidence to reach a definitive conclusion.
3. *Not a human bite mark* – Human teeth did not create the mark.

Almost all the injuries that were present on this child had similar *class characteristics*. They were round/oval in shape and consisted of two opposing arches. The arches were separated at the base by open space. The indentation marks caused by the individual teeth were clearly visible. For these reasons it was concluded that the injuries were human bite marks.

Commonly used methods for bite mark analysis include metric analysis, pattern analysis and the combination of both.¹⁶ Several researchers have tried to calculate the minimum number of concordant points necessary to establish a positive identification. To establish the identity of the perpetrator in a bite mark case it is necessary to prove beyond any reasonable doubt that another individual could not leave an identical print to that of the mark concern. This can be achieved with a single unique feature or by the effect of large number of features considered together. It has been said that the conclusion of the forensic analysis of a

skin bite mark should never exceed the standard of "high degree of certainty" and "absolute certainty" or "100% sure" is not a standard that can be used.^{17, 18,}

According to the ABFO guidelines¹⁵ only the injuries recognized as "Bite Marks" which show class characteristics and individual characteristics should be analyzed and compared with the suspects' dentition. They also provide a range of terms to describe the link between the bite mark and the suspect. These are:

1. The biter
2. The probable biter
3. Not excluded as the biter
4. Excluded as the biter
5. Inconclusive

The ABFO does not support a conclusion of "The Biter" in an open population case.¹⁵ The recommended conclusions for an open population case are either "Not excluded, Excluded or Inconclusive".

It is a fact that all bite marks cannot be analyzed to an extent that could be presented as evidence in a court of law, even though bite marks may be the only evidence that connect the suspect to the crime. Even inconclusive evidence gathered from bite mark analysis may help in better medical management of the case as in the case described above. Bite mark evidence is considered as difficult but highly persuasive especially to the jurors.¹⁹ For this same reason, there is a very high onus on the forensic odontologist to do an impartial investigation in bite mark cases.^{17, 18}

To increase the objectivity in bite mark analysis and interpretation, and to reach more certainty, extraction of the suspect's DNA (Saliva DNA) from bite mark can be performed.²⁰ The double swab technique with control swabs is the recommended practice.²¹ For positive results the area of the bite should not have been washed prior to swabbing. In the case presented, swabbing was not done as the child had bathed on the morning of the forensic odontological examination

In cases where children have been subjected to bite mark injury, it is important to compare the injury pattern

with the dentitions of all the individuals who have access to the child. This includes the parents, care givers as well as siblings and play mates.

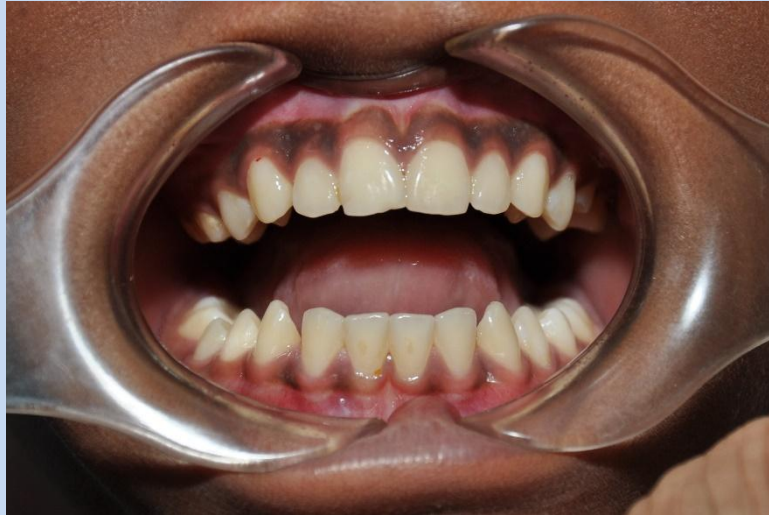

Fig.5: *The sister's dentition*

CONCLUSION

Bite mark injuries can be considered as a unique type of patterned/tool- mark injury. Identifying an injury as a bite mark automatically qualifies it to be called as tool-mark injury and creates a requirement to identify the tool. Identifying the tool in this unique incident (biting) inevitably leads to the identification of the perpetrator which is not so with other types of tool-mark injuries. Hence if a mark similar to that of a bite mark is present on a person (victim or a perpetrator) all efforts must be taken to conduct a complete analysis. Especially in cases of abuse and neglect, identification of the injury as a bite mark and providing information that may subsequently lead to the identification of the perpetrator as in the case described above, may serve a great function towards the better medical management of the case. Bite marks do not always present as circular or oval patterned injuries. The shape of the injury can vary depending on the site of the injury, shape of the causing dentition as well as the position and movement of the victim during the

incident. Recognition, analysis and identification of a bite mark injury is challenging and requires special investigation and should never be performed by clinicians with no forensic background. It is important to stress the fact that bite mark evidence to be presented and accepted by a court of law it needs to be of very high quality.

The ultimate goal of managing cases of child abuse and neglect is to prevent subsequent injury to the child and to bring perpetrators to justice. These cases of abuse and neglect are usually managed by pediatric specialists with forensic medicine practitioners. As for many other cases²², the case presented confirms the importance of forensic odontological involvement in investigations of cases of child abuse and neglect. It further exemplifies the importance of communication and collaboration between pediatric specialists and forensic practitioners, and emphasizes the multidisciplinary approach in investigation and management of cases of child abuse.

ACKNOWLEDGEMENTS

The author acknowledges the support given by Dr. Ruhul Haq, Consultant

Judicial Medical Officer at the Institute of Legal Medicine and Toxicology, Colombo, Sri Lanka.

REFERENCES

1. Pretty IA, Sweet DJ. *The Judicial view of bite marks within the United State Criminal Justice System. J Forensic Odontostomatol* 2006; 24: 1-11.
2. Atsü SS, Gökdemir K, Kedici PS, Ikyaz YY. *Bite marks in forensic odontology. J Forensic Odontostomatol* 1998; 16(2):30-4.
3. Bernitz H, van Heerden WFP, Solheim T, Owen JH. *A technique to capture, analyze and quantify anterior teeth rotations for application in court cases involving tooth marks. J Forensic Sci* 2006; 51(3):624-629.
4. Vale GL. *Dentistry, bite marks and the investigation of crime. J Calif Dent Assoc* 1996; 24(5): 29-34.
5. Clark DH. *Bite mark examination procedures: victims and suspects.* In: Clark DH(ed). *Practical forensic odontology.* Oxford, Butterworth-Heinemann; 1992. p128-37.
6. Pretty IA, Sweet DJ. *Anatomical location of bite marks and associated findings in 101 cases from the United States. J Forensic Sci* 2000; 45(4):812-4.
7. Gold MH, Roenigk HH, Smith ES, Pierce LJ. *Human bite marks- Differential diagnosis. Clin Pediatr (Phila)* 1989; 28(7):329-31.
8. Pretty IA. *Forensic dentistry: 2. Bite marks and bite injuries. Dental Update* 2008; 35(1):48-61.
9. James H, Cirillo GN. *Bite mark or bottle top?. J Forensic Science* 2004; 49(1):119-21.
10. Johansen RJ, Bower CM. *Digital Analysis of Bite Mark Evidence Using Adobe Photoshop®.* Santa Barbra, California. Forensic Imaging Services; 2000.
11. Wright FD, Dailey JC. *Human bite marks in forensic dentistry. Dent Clinic North Am* 2001; 45(2): 365-97.
12. Bernitz H. *Concepts to elucidate the pattern-associated analysis of tooth marks in court. SADI* 2005; 60 (2):62-65.
13. Whittaker DK, MacDonald DG. *Bite marks in flesh.* In: Whittaker DK, MacDonald DG (ed.). *A colour atlas of forensic dentistry.* England, Wolf Medical Publications 1989.
14. Whittaker DK. *The principles of Forensic Dentistry: 2 Non accidental injuries, bite marks and archeology. Dental Update* 1990; 17(9):386-90.
15. American Board of Forensic Odontology, Diplomates Reference Manual [Internet]. [updated. August 2013]; Available from :www.abfo.org
16. Bernitz H, Piper SE, Solheim T, Van Nickerk PJ, Swart TJ. *Comparison of bite marks left in foodstuff with models of the suspects' dentition as a means of identifying a perpetrator. J Forensic Odontostomatol* 2000; 18:27-31.
17. Bernitz H, Owen JH, Willie F, van Heerden P, Solheim T. *An integrated technique for the analysis of skin bite marks. J Forensic Sci* 2008; 53(1):194-198.
18. Whittaker DK. *Bite marks – the criminal's call card. Br Dent J* 2004; 196:237.
19. Aksu MN, Gobetti JP. *The past present legal weight of bite marks as evidence. Am J Forensic Med Pathol* 1996; 17(2):136-40.
20. Sweet D, Lorente JA, Valenzuela A, Lorente M, Villanueva E. *PCR –based DNA typing of saliva strains recovered from human skin. J Forensic Sci* 1997; 42(3):447-451. Sweet D, Lorente M, Lorente JA, Valenzuela A, Villanueva E. *An improved method to recover saliva from human skin: the double swab technique. J Forensic Sci* 1997; 42(2):320-322.
21. Sweet D, Lorente M, Lorente JA, Valenzuela A, Villanueva E. *An improved method to recover saliva from human skin: the double swab technique. J Forensic Sci* 1997; 42(2):320-322.
22. Nuzzolese E, et al. *Child abuse and dental neglect: the dental team's role in identification and prevention. Int J Dent Hygiene* 2009; 7:96-101.
