

Artificial intelligence in age and sex determination using maxillofacial radiographs: A systematic review

Copyright © 2024 International Organization for Forensic Odonto-Stomatology - IOFOS

Sraddha Singh¹, Bhoopendra Singh¹, Shanu Kumar¹

¹ Department of Forensic medicine & Toxicology, Rajendra Institute of Medical Science, Ranchi, India

Corresponding author:
sshreddha72@gmail.com

The authors declare that they have no conflict of interest.

KEYWORDS

Artificial Intelligence,
Convolutional Neural
Networks,
Artificial Neural Networks,
Machine Learning,
Deep learning,
Mandible,
Forensic Odontology,
OPG,
Lateral Cephalogram

J Forensic Odontostomatol

2024. Apr;(42): 1-30:37

ISSN :2219-6749

DOI doi.org/10.5281/zenodo.11088513

ABSTRACT

In the past few years, there has been an enormous increase in the application of artificial intelligence and its adoption in multiple fields, including healthcare. Forensic medicine and forensic odontology have tremendous scope for development using AI. In cases of severe burns, complete loss of tissue, complete or partial loss of bony structure, decayed bodies, mass disaster victim identification, etc., there is a need for prompt identification of the bony remains. The mandible, is the strongest bone of the facial region, is highly resistant to undue mechanical, chemical or physical impacts and has been widely used in many studies to determine age and sexual dimorphism. Radiographic estimation of the jaw bone for age and sex is more workable since it is simple and can be applied equally to both dead and living cases to aid in the identification process. Hence, this systematic review is focused on various AI tools for age and sex determination in maxillofacial radiographs. The data was obtained through searching for the articles across various search engines, published from January 2013 to March 2023. QUADAS 2 was used for qualitative synthesis, followed by a Cochrane diagnostic test accuracy review for the risk of bias analysis of the included studies. The results of the studies are highly optimistic. The accuracy and precision obtained are comparable to those of a human examiner. These models, when designed with the right kind of data, can be of tremendous use in medico legal scenarios and disaster victim identification.

INTRODUCTION

Forensic odontology deals with the proper administration and evaluation of dental evidence in criminal or civil legal proceedings in the interest of justice.¹ It involves identification by assessing and analysing the unique structures in the oral cavity.² Identification is the most important aspect of forensic and the application of forensic odontology involves teeth and jaw bones to aid in the process of identification. Identification through age and sex of bony remains is viable due to its ability to last longer under physical, mechanical stress.³ Identification is attained with 100% accuracy if a complete skeleton is available, although this is rarely the case. In cases of mass disasters, with complete or partial loss of human structure or burns, it is impossible to find an intact human skeleton.⁴ For age and sex determination after pelvis,

skull is the most dimorphic structure. The Mandible being the strongest bone of the skull, is the bone of choice for age and sex determination.^{5,6} Radiographs are simple, accessible, and cost effective and demonstrate high accuracy for age and sex determination. They can be easily advised in both living and dead.⁷

Artificial intelligence (AI) can be described as an intelligent computer system with the unique ability to mimic human potential in decision making, problem solving, understanding language and learning. AI models developed using machine learning, can predict events with given sets of observations in the form of images or data. AI not only overcomes the subjectivity of any diagnosis or individual examination but also reduces the overall cost.⁸ Deep learning is another type of neural networks where the model on its own learns about the data and how to process the given data. Deep learning neural network have neurons in hidden layers in thousands and millions.^{9,10} AI and its advent in the field of medical science have made the possibility of sound diagnosis and prompt prediction with decision making achievable.¹¹ The major feature of decision making with already known observation is the main feature of AI which will be of great significance in the field of

forensic odontology. Studies have shown that AI has the accuracy and precision equivalent to trained examiner in age and sex determination of the individuals.^{12,13} Hence this systematic review is aimed at reporting on Artificial intelligence in age and sex determination in forensic odontology.

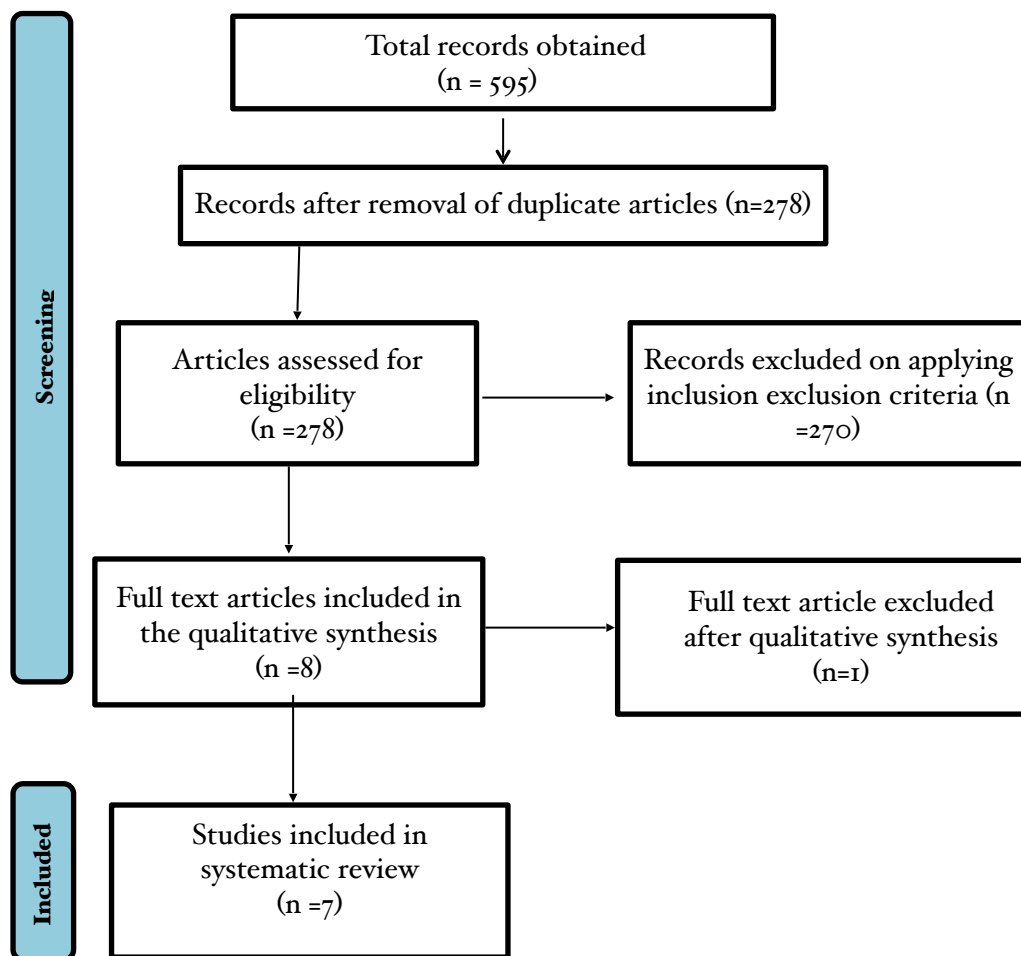
MATERIALS AND METHODS

Search strategy and Review framework

To conduct this systematic review, articles that were based on the application of artificial intelligence in the mandible for age and sex determination were selected. Preferred reporting items for systematic reviews and meta-analyses PRISMA guideline for diagnostic test accuracy were used Fig.1.¹⁴ The data search was conducted through various search engines, namely Pubmed, Cochrane, Google Scholar, and Scopus. The search duration spans 10 years, from January 2013 to March 2023. The following key words were used in various combinations to improve the search strategy like Artificial Intelligence (AI) Convolutional Neural Networks (CNN), Artificial Neural Networks (ANN), Mandible, Forensic Odontology, OPG, and Lateral Cephalogram. The PICO guideline was used for searching for the right kind of study to be included in the systematic review (Table 1).

Table 1. Table showing PICO (P = Population, I = Intervention, C = Comparison, O = Outcome) and Research Question.

RESEARCH QUESTION	
How will Artificial intelligence tool be used in mandibular age and sex determination in forensic cases?	
Population	Patients maxillofacial radiographs (Orthopantomogram, lateral Cephalogram, CBCT images)
Intervention	AI algorithms for age estimation and sex determination
Comparison	Comparison across different AI models, reference standards, expert opinions
Outcome	Measurable or predictive outcomes such as accuracy, Correlation Coefficient, sensitivity, specificity, ROC = receiver operating characteristic curve, AUC = Area Under the Curve.

Figure 1. PRISMA Flow chart showing the selection of articles for the systematic review.

Methodology

For the preliminary search, 585 articles were identified using database searches, and through other sources, an additional 11 articles were identified. The net article available after the first stage was 595. The retrieved articles were full texts and abstracts. In the first stage articles were chosen, based on their titles and the abstracts that addressed our research question. In the second stage, 278 articles were eligible for review after the removal of 278 articles because of duplication. The following inclusion and exclusion criteria were considered for the eligibility of the studies:

Inclusion criteria

The article must be about the application of AI to the mandibular bone. There should be specific mention of the AI based model used in the study. There should be a specified data set for each model to be applied for age or sex determination.

There should be a measurable outcome to assess the role of AI in the study.

Exclusion criteria

Articles on tools apart from AI technology.
Articles with only abstracts and not full text.
Articles in languages other than English.

Data management

Post application of the above eligibility criteria, only 8 articles were obtained. Qualitative assessment was done for each article based on QUADAS 2 (Quality Assessment and Diagnostic Accuracy Tool) by the author.¹⁵ One article was found to be a misfit amongst the 8 articles (Fig 1). 7 articles were available for final analysis, and these were read in full length so that AI application in the mandibular age and sex determination could be analysed. Each article was discussed among 4 domain namely patient selection, index test, reference standard, and flow

and timing. For each domain risk of bias was assessed in terms of high risk, unclear risk and

low risk. Patient selection, index test, reference standard also assessed the applicability.

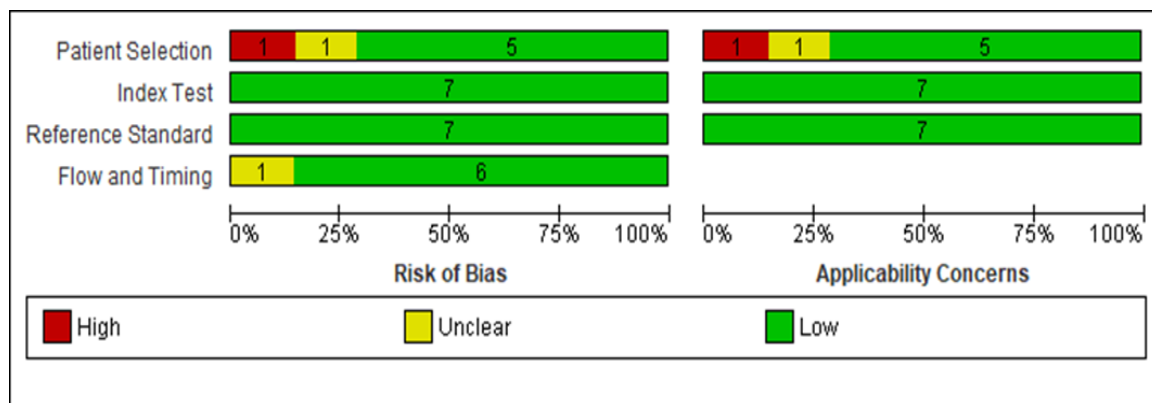
RESULTS

While conducting the systematic review, 7 articles were analysed for quantitative data. All studies that were finally analysed were conducted in the past five years, although inclusion criteria stated a duration of 10 years. All the studies were based on the AI tool and its application in mandibular age and sex determination. The models used in the study were ANN¹⁶, ML¹⁷, KCNN-KNN¹⁸, BCNN¹⁹, and CNN.²⁰⁻²² These neural network models were used to evaluate panoramic radiographs^{16-20,22} and lateral cephalograms.²¹

Risk of bias

Risk of bias assessment was conducted under 4 domains, in patient selection, one study showed high risk¹⁷ and one showed unclear risk.²⁰ Overall, 72% of studies showed low risk in patient selection. All studies focused on age and sex determination through the AI models therefore, there was an overall low risk for reference standards and index test. For the flow and timing of the study, one study showed unclear risk¹⁷. This risk of bias in assessment and applicability concern is shown in Fig. 2. The applicability showed similar results.

Figure 2. Figure showing the number of studies and their proportion under high risk, unclear and low risk categories for both Risk of Bias and Applicability Concerns.



DISCUSSION

Age and sex determination play a crucial role in the process of identification and in establishing an anthropological profile.²³ The resilience of jaw bones provides immense information for establishing the identity of any unknown body. Identification through bony and dental remains is critical in cases of chemical burns, burns, and complete or partial tissue loss.²⁴ The traditional morphometric measurement used for age and sex

determination in radiographs fails to provide the proper identification. The ability of artificial intelligence to minimise error and precision in feature assessment, followed by prompt prediction, makes it a tool of choice.¹⁵

In the present systematic review, an effort has been made to analyse various AI tools for prompt identification involving age and sex in maxillofacial radiographs (Table 2).

Table 2. Details of studies in the systematic review involving AI based models in age and sex determination using maxillofacial radiographs.

Sl. No.	1.	2.	3.	4.	5.	6.	7.
Authors	Banjsak et al ²²	Baydogan et al ²⁰	Patil et al ¹⁶	Khazaei et al ²¹	Lee et al ¹⁷	Back et al ¹⁹	Sharifonnasab et al ¹⁸
Year of Publication	2020	2022	2020	2022	2022	2020	2022
Algorithm	CNN	CNN	ANN	CNN	ML	BCNN	HCNN-KNN
Objective	Convolutional neural network to estimate age of archaeological skull remains	Age detection for Deep learning from Dental panoramic radiographs	Artificial neural network for gender determination using mandibular parameters	CNN model for sex determination using lateral cephalogram	Machine learning algorithm for age group prediction using panoramic metric parameters	Age estimation using Bayesian convolutional neural network	Hybrid HCNN-KNN Model for Age estimation accuracy in orthopantomography
Training data set	3228	627	509	1180	471	2400	1537
Validation data set	403	Not clear	63	296	Not clear	Not clear	384
Testing data set	89	Not clear	63	296	Not clear	Not clear	none
Comparison	3 models	none	3 models	3 models	none	none	none
Study factor	Mandibular architecture and teeth	Mandible and teeth	Mandibular parameters	Mandible	Mandible and dental metric parameters	Upper and lower jaws	Upper and lower jaws
Modality	Orthopantomograms	Orthopantomograms	Orthopantomograms	Lateral cephalogram	Orthopantomograms	Orthopantomograms	orthopantomograms
Result	Model1:53% Model2:42% Model3:73%	84%	Discriminant analysis:69.1% Logistic regression:69.9% ANN:75%	DenseNet 121:90% ResNet:62% VGG 75%	87%	Concordance correlation coefficient ccc=0.91	99.80%
Effective(+) Non-effective(-) Neutral(-)	Effective(+)	Effective(+)	Effective(+)	Effective(+)	Effective(+)	Effective(+)	Effective(+)
Outcome	The study demonstrated noteworthy accuracy in placing images in correct age group	The study depicted high accuracy of dental age estimation	Outcome of the study depicts higher accuracy for gender prediction using ANN model	CNN based DenseNet121 has high predictive accuracy in sex determination using lateral cephalometric images	In machine learning models age group prediction accuracy was more than acceptable	Bayesian CNN quantifies the predictive uncertainty which is important in legal context	The model correctly classified age with 99.8% accuracy. Evaluating the proposed model on a new dataset with different races also proved the superior performance of the model
Recommendation	Further development of neural net and training would offer better results	In future studies, different feature extraction and increasing number of data to be included for state-of-the-art classifier	The results also needs to be extrapolated using larger population considering other confounding factors like origin, race, age, masticatory muscles	Further studies with larger sample size are desirable to more accurately determine sex correctly on larger scale	Additional classification with larger sample size is needed to determine whether the prediction performance will increase	Results are encouraging although the accuracy is not yet at the level that warrants routine application	none

In a study conducted by Back et al¹⁶ for age estimation (15-25 years age), Bayesian Convolutional neural network was used to attain the concordance correlation coefficient $ccc=0.910$. Age estimation in orthopantomograms was formulated using a regression task and CNN was designed in which Inception V3 architecture was used. There was a considerable agreement between true age and predicted age; however, the mean absolute error was almost 2 years, which is highly unacceptable for legal purposes. The results were encouraging for the application of AI in the form of BCNN, but not to the level that confirms routine application.

Banjsak et al²² used CNN for archaeological age estimation (19 to 85 years of age) through transfer learning. A VGG architecture pre trained on the ImageNet feature extractor was used. Three models were used for age prediction by just changing the hyperparameters. Model 1 showed 53% accuracy, Model 2 showed 42% accuracy, and Model 3 showed 73% accuracy. This study demonstrated a noteworthy accuracy that should be considered for further analysis using an orthopantomogram.

In another study conducted by Baydogan et al²⁰ for age determination (2 to 13 and 13 to 31 years) using orthopantomograms, CNN was used with the Alexnet architecture for feature extraction, followed by four classification algorithms. The K nearest neighbour algorithm showed the highest accuracy (84% accuracy). This study depicts high accuracy with the intervention of AI in age determination.

In a study conducted by Patil et al¹⁶ for sex determination using ANN, orthopantomogram was used. Logistic regression and discriminant analysis were used for sex determination, along with an artificial neural network. ANN had an accuracy of 75%, much higher than the other two models. This study stated that ANN could be a promising prediction tool for sex determination in forensics.

Sharifonnasabi et al¹⁸ conducted a study on orthopantomograms for age determination (15 to 23 years) using the HCNN-KNN model. This model had a very high accuracy of 99.8% for age determination. The precision was as high as ± 6 months. Principal component analysis was used to compensate for overfitting. This study proves that a substantial model design could facilitate prompt age classification.

Khazaei et al²¹ conducted a study on sex

determination from lateral cephalometric radiographs using CNN. The three models, DenseNet, ResNet, and VGG, were evaluated for their ability to correctly determine the sex of the lateral cephalogram. DenseNet 121 architecture depicted the highest accuracy of 90%. The study also showed the importance of transfer learning to attain high accuracy in sex determination. The study gives desirable results and can be implemented with a larger sample size.

In a study conducted by Lee et al¹⁷ for age determination (11 to 69 years), machine learning was used. Five machine learning models were formulated. Each model demonstrated high accuracy for age group prediction. Overall accuracy of 87% was achieved, although a larger sample size is needed to determine the true prediction accuracy.

The above mentioned studies have used various models in order to provide age or sex determination with accuracy higher than the already existing methodology. All these studies have certainly high accuracy, but translating the results into routine applications will require a deeper and more detailed study. Although the present study is based on AI application on mandibular bone, expanding the application to dental age and sex determination can be of great help if interpreted together. Teeth based age and sex determination using a hybrid transformer model can add significant value to overall results.²⁶ The ability of AI to provide objective and accurate decision making can be used explicitly in other domains like bitemark, facial identification, and dental comparison.²⁷ AI is a game changer when the correct data is available. Data in the form of maxillofacial radiographs is a prerequisite for such studies. In several studies deep convolutional network have proven to be of high accuracy and practical significance with accuracy as high as 94.7%.²⁸ The advent of AI in the field of forensic medicine and odontology will certainly aid in quality decision making. This overarching domain requires skilled manpower and high quality data to provide highly objective and accurate results. Artificial intelligence provides an opportunity to revolutionise the discipline, but comes with certain challenges. The issue of data privacy being one of the major hindrances, followed by the availability of a huge amount of good quality data is a challenge. This in turn could perpetuate bias and amplify incorrect discrimination ability.²⁹ In order to

mitigate the possible disadvantages offered by AI, extensive research, an expanding knowledge base, and exploring the true potential of deep learning and machine learning algorithms are to be done. Good quality data is the cornerstone of all AI applications. This data can be helpful for obtaining prompt results in age and sex determination in real-life scenarios, and could be of great help in cases of mass victim identification, decomposed bodies, and criminal cases where it is important to establish age and sex along with other parameters.

CONCLUSION

We are at the doorstep of another technological advancement, which will be directed by artificial intelligence. AI and its ability to mimic human capabilities and decision-making are already

taking over various sectors. Forensic medicine, forensic odontology, and anthropology are no exceptions. The advent of AI, with the help of good-quality data and vast information, can be an excellent tool. For age and sex determination, quality and quantity of data are imperative to facilitate the development of proper models or tools that the authorities can rely upon. The development of such a model can be utilised by medical, legal, police, and forensic authorities. Therefore, future studies are recommended by utilising the application of AI in age and sex determination in a wider maxillofacial radiographic data set.

Statements and Declarations:

No competing interest have appeared to affect the work.

REFERENCES

- Luntz LL. History of forensic dentistry. *Dent Clin North Am.* 1977 Jan;21(1):7-17.
- Johnson A. A Morphological Study of Tongue and its Role in Forensics Odontology. *J Forensic Sci Crim Investig* [Internet]. 2018 Feb 19 [cited 2023 Apr 21];7(5). Available from: <https://juniperpublishers.com/jfsci/JFSCI.MS.ID.555723.php>
- Berketa JW, James H, Lake AW. Forensic odontology involvement in disaster victim identification. *Forensic Sci Med Pathol.* 2012 Jun;8(2):148-56.
- Scheuer: Application of osteology to forensic medicine - Google Scholar. [cited 2023 Apr 21]. https://scholar.google.com/scholar_lookup?journal=Clin+Anat&title=Application+of+osteology+to+forensic+medicine&author=L+Scheuer&volume=15&publication_year=2002&pages=297-312&pmid=12112359&
- Saini V, Srivastava R, Rai RK, Shamal SN, Singh TB, Tripathi SK. Mandibular ramus: an indicator for sex in fragmentary mandible. *J Forensic Sci.* 2011 Jan;56 Suppl 1:S13-16.
- More CB, Vijayvargiya R, Saha N. Morphometric analysis of mandibular ramus for sex determination on digital orthopantomogram. *J Forensic Dent Sci.* 2017;9(1):1-5.
- Johnson A, Singh S, Thomas A, Chauhan N. Geometric morphometric analysis for sex determination using lateral cephalograms in Indian population: A preliminary study. *J Oral Maxillofac Pathol JOMFP.* 2021;25(2):364-7.
- Schwendicke F, Samek W, Krois J. Artificial Intelligence in Dentistry: Chances and Challenges. *J Dent Res.* 2020 Jul;99(7):769-74.
- Javed S, Zakirulla M, Baig RU, Asif SM, Meer AB. Development of artificial neural network model for prediction of post-streptococcus mutans in dental caries. *Comput Methods Programs Biomed.* 2020 Apr;186:105198.
- Khanagar SB, Al-Ehaideb A, Maganur PC, Vishwanathaiah S, Patil S, Baeshen HA, et al. Developments, application, and performance of artificial intelligence in dentistry - A systematic review. *J Dent Sci.* 2021 Jan;16(1):508-22.
- Park WJ, Park JB. History and application of artificial neural networks in dentistry. *Eur J Dent.* 2018 Oct;12(4):594-601.
- An automated technique to stage lower third molar development on panoramic radiographs for age estimation: a pilot study. - PMC [Internet]. [cited 2023 Apr 22]. Available from: <https://www.ncbi.nlm.nih.gov/pmc/articles/PMC6100230/>
- Roh BY, Lee WJ, Seo JU, Lee UY, Lee SS. Analysis of forensic odontological examinations at the National Forensic Service of Korea from 2011 to 2015. *Leg Med Tokyo Jpn.* 2018 May;32:37-42.
- McGrath TA, Alabousi M, Skidmore B, Korevaar DA, Bossuyt PMM, Moher D, et al. Recommendations for reporting of systematic reviews and meta-analyses of diagnostic test accuracy: a systematic review. *Syst Rev.* 2017 Oct 10;6(1):194.
- Whiting PF, Rutjes AWS, Westwood ME, Mallett S, Deeks JJ, Reitsma JB, et al. QUADAS-2: a revised tool for the quality assessment of diagnostic accuracy studies. *Ann Intern Med.* 2011 Oct 18;155(8):529-36.
- Patil V, Vineetha R, Vatsa S, Shetty DK, Raju A, Naik N, et al. Artificial neural network for gender determination using mandibular morphometric parameters: A comparative retrospective study. *Jin Z, editor. Cogent Eng.* 2020 Jan 1;7(1):1723783.
- Lee YH, Won JH, Auh QS, Noh YK. Age group prediction with panoramic radiomorphometric parameters using machine learning algorithms. *Sci Rep.* 2022 Jul 9;12:11703.
- Sharifonnasabi F, Jhanjhi NZ, John J, Obeidy P, Band SS, Alinejad-Rokny H, et al. Hybrid HCNN-KNN Model Enhances Age Estimation Accuracy in Orthopantomography. *Front Public Health.* 2022;10:879418.
- Back W de, Seurig S, Wagner S, Marré B, Roeder I, Scherf N. Forensic age estimation with Bayesian convolutional neural networks based on panoramic dental X-ray imaging. 2022 Jul 13 [cited 2023 Apr 23];

- Available from: <https://openreview.net/forum?id=SkesoBY49E>
20. Baydoğan MP, Baybars SC, Tuncer SA. Age Detection by Deep Learning from Dental Panoramic Radiographs. *Artif Intell Theory Appl*. 2022 Oct 1;2(2):51-8.
 21. Khazaei M, Mollabashi V, Khotanlou H, Farhadian M. Sex determination from lateral cephalometric radiographs using an automated deep learning convolutional neural network. *Imaging Sci Dent*. 2022 Sep;52(3):239-44.
 22. Banjšak L, Milošević D, Subašić M. Implementation of artificial intelligence in chronological age estimation from orthopantomographic X-ray images of archaeological skull remains. *Bull Int Assoc Paleodontology*. 2020 Dec 22;14(2):122-9.
 23. Wang X, Liu Y, Miao X, Chen Y, Cao X, Zhang Y, et al. DENSEN: a convolutional neural network for estimating chronological ages from panoramic radiographs. *BMC Bioinformatics*. 2022 Oct 14;23(3):426.
 24. Pretty IA. Forensic dentistry: 1. Identification of human remains. *Dent Update*. 2007 Dec;34(10):621-2, 624-6, 629-630 passim.
 25. Sikka A, Jain A. Sex Determination of Mandible: A Morphological and Morphometric Analysis. *Int J Contemp Med Res*, 2016;3: 1869-72.
 26. Fan F, Ke W, Dai X, Shi L, Liu Y, Lin Y, Cheng Z, Zhang Y, Chen H, Deng Z. Semi-supervised automatic dental age and sex estimation using a hybrid transformer model. *Int J Legal Med*. 2023 May;137(3):721-731. doi: 10.1007/s00414-023-02956-9. Epub 2023 Jan 31.
 27. Vodanović M, Subašić M, Milošević DP, Galić I, Brkić H. Artificial intelligence in forensic medicine and forensic dentistry. *J Forensic Odontostomatol*. 2023 Aug 27;41(2):30-41.
 28. Ilić I, Vodanović M, Subašić m. Gender Estimation from Panoramic Dental X-ray Images using Deep Convolutional Networks. *IEEE EUROCON 2019 -18th International Conference on Smart Technologies*, 2019, pp. 1-5, Novi Sad, Serbia, 1-4 July 2019. doi: 10.1109/EUROCON.2019.8861726
 29. Vodanović M, Subašić M, Milošević DP, Galić I, Brkić H. Artificial intelligence in forensic medicine and forensic dentistry. *J Forensic Odontostomatol*. 2023 Aug 27;41(2):30-41.