

# ANALYSIS OF RUGAE IN BURN VICTIMS AND CADAVERS TO SIMULATE RUGAE IDENTIFICATION IN CASES OF INCINERATION AND DECOMPOSITION

*M.Muthusubramanian, K.S.Limson, R.Julian*

*Department of Prosthetic Dentistry, Tamilnadu Government Dental College and Hospital, Chennai, India*

## ABSTRACT

The most challenging situations in Forensic Odonto-Stomatology are mass disasters, where the forensic dentist is usually confronted with charred human remains or heavily decomposed or fragmented bodies. This article determines the extent of preservation of palatal rugae for use as an alternative identification tool in such situations, using a study group comprising burn victims and cadavers simulating forensic cases of incineration and decomposition. The thermal effects and the decomposition changes on the palatal rugae of burn victims with panfacial third degree burns and human cadavers in storage were respectively assessed and graded on a new scale. Ninety three percent of burn victims and 77% of human cadavers had Grade 0 changes (normal). When changes were noted, they were less pronounced than the generalized body involvement of burns in burn victims and the generalized body decomposition of human cadavers.

**(J Forensic Odontostomatol 2005;23:26-9)**

**Key words:** palatal rugae, forensic identification, burn victims, human cadavers

## INTRODUCTION

Nowadays deaths due to high-speed transportation accidents and acts of terrorism are on the rise and identification of these victims is a major goal of forensic science.<sup>1</sup> Methods of identification commonly employed are visual identification, fingerprint and dental records comparison and DNA profiling. Although DNA profiling is accurate, it is expensive and time consuming for use in large populations.<sup>2</sup> Visual identification and fingerprints are limited by postmortem changes associated with time, temperature and humidity<sup>3</sup> but dental tissues have been

shown to withstand these conditions.<sup>4-8</sup> Among the oral tissues palatal rugae are permanent, unique to each individual and can establish identity through discrimination.<sup>9,10</sup> Palatal rugae, due to their internal position, are protected from trauma and high temperatures by lips, cheek, tongue and buccal pad of fat teeth and bone and do not demonstrate age-related changes.<sup>11,12</sup> In spite of these merits, rugae have not often been used as a widespread forensic tool. This study throws light on the usefulness of rugae in forensic situations of incineration and decomposition.

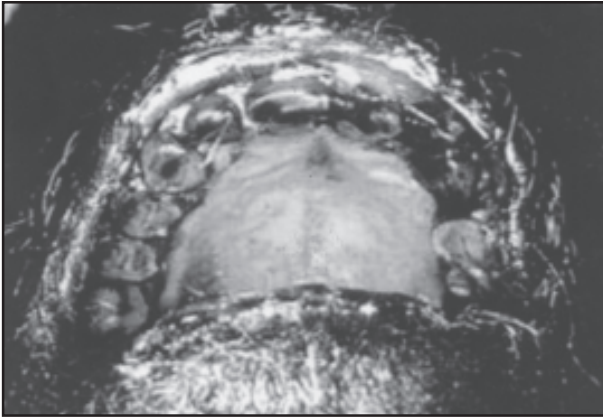
## MATERIALS AND METHODS

### Study groups

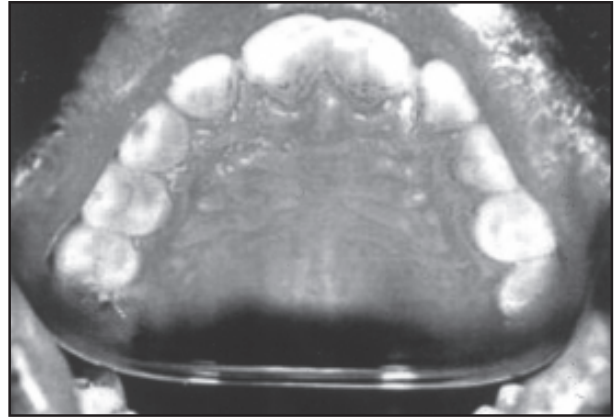
Two study groups were formed simulating conditions found at mass disasters. One group consisted of thirty burn victims and the other consisted of thirty human cadavers. Both males and females aged 18-65, of south Indian Dravidian ethnicity, and either dentate or partial dentate with no missing teeth in the anterior maxilla were examined.

### Burn victims

Burn victims treated at the Department of Burns, Kilpauk Medical College Hospital, Chennai for pan facial third degree burns (full thickness burns characterised by multicoloured denatured layers, dry and insensitive to pain involving skin, subcutaneous tissues, adnexal structures and nerves which usually requires skin grafting) were selected to assess the influence of fire on changes to palatal rugae. All subjects were examined within 72 hours of the accident (following emergency treatment). The cause of the fire producing the injuries was not considered. Burn victims were clinically assessed and the condition of the palatal rugae was graded based on the degree of thermal effects observed.



**Fig.1:** Palatal rugae of a burn victim- Grade 0



**Fig.2:** Palatal rugae of a human cadaver-Grade 1

- Grade 0: Mucosa pink in colour. Palatal rugae unaltered.
- Grade 1: Inflammation of mucosa with mild erythema and oedema. Rugae clearly identifiable.
- Grade 2: Erythematous mucosa with bullae and ulcerations. Rugae faintly identifiable.
- Grade 3: Blistered and necrosed mucosa. Blotchy-red appearance. Rugae not identifiable.

Changes observed in the rugae were compared with the percentage of total body surface involved with burns (TBSA) classified using the 'Rule of Nine', in which body regions are grouped as a multiple of 9% of the total (ie 9% - head, neck and each arm, 18% - anterior trunk, posterior trunk and each leg, 1% - palms and genitals) to provide an easy estimation of the extent of the surface area of the burns.<sup>13</sup>

#### Human cadavers

Human cadavers stored in the mortuary of the Institute of Forensic Medicine, Madras Medical College Hospital, were selected to assess the preservation of palatal rugae after death. Cadavers were stored in the mortuary at temperature of 5° Celsius and relative humidity of 30-40% within 12 hours of autopsy and kept for a minimum period of 7 days. Condition of the palatal rugae was assessed clinically in the cadavers and graded based on the changes observed on the eighth day.

- Grade 0: Mucosa pink in colour. Palatal rugae clearly identifiable.
- Grade 1: Mucosa blanched. Drying of oral cavity. Rugae identifiable.
- Grade 2: Mucosa oedematous. Tissues slip over the rugae. Rugae faintly identifiable.
- Grade 3: Swelling and necrosis of mucosa. Rugae not identifiable. Fungal growth was not ascertained.

The stage of decomposition of each cadaver, as described by Clark et al.,<sup>14</sup> was assessed.

- Stage I: Early putrid odour, lividity fixed, rigor waning.
- Stage II: Intensive livor, no rigor, early skin slippage, drying of lips and fingers.
- Stage III: Prominent haemolysis, skin slip easily, tissues soft and slick.
- Stage IV: Early body swelling, discolouration of head, bullae formation.

These stages were then compared with the condition of the palatal rugae in each body.

Photographic records of burn victims and cadavers were taken using a Canon SLR Camera\* with 35-80 standard zoom and flash guide No.1. A palatal mirror was used to obtain adequate opening and exposure of rugae in photographs. Figure 1 shows rugae of a burns victim and Figure 2 show rugae of a cadaver.

\*Canon Inc, Tokyo, Japan

**Table 1:** Thermal effects in palatal rugae among panfacial third-degree burn victims

Grade	Burn Victims Number
Grade 0	28
Grade 1	0
Grade 2	2
Grade 3	0

**Table 2:** Comparison of thermal changes observed in rugae with the total body surface area (TBSA) involved in burns

%BURNS (TBSA)	Rugae Changes	Burn Victims
50-59	Grade 0	2
60-69	Grade 0	19
70-79	Grade 0	5
80-89	Grade 0	2
	Grade 2	2

## RESULTS

Grade 0 thermal effects in 28 subjects and Grade 2 thermal effects in two subjects were noted in the palatal rugae of burn victims (Table 1). The thermal effects in the palatal rugae of burn victims were compared to the extent of generalised body involvement with burns. Of the subjects with Grade 0 thermal effects in their palatal rugae: two subjects had 50-59% burns to total body surface area (TBSA), 19 subjects had 60-69% burns TBSA, five subjects had 70-79% burns TBSA and two subjects had 80-89% burns TBSA. The two subjects with Grade 2 thermal effects in their palatal rugae had 80-89% burns TBSA (Table 2).

The palatal rugae of the human cadavers in storage showed Grade 0 changes in 23 cadavers, Grade 1 changes in two cadavers, Grade 2 changes in three cadavers and Grade 3 changes in two cadavers (Table 3).

The decomposition changes in the palatal rugae of cadavers were compared to the extent of generalised body decomposition, of the 23 cadavers with Grade 0 decomposition changes in their palatal rugae, eight cadavers were in Stage II and 15 cadavers were in Stage III body decomposition respectively. Two cadavers with Grade 1 decompo-

**Table 3:** Decomposition changes in palatal rugae among the human cadavers in storage

Grade	Cadavers Number
Grade 0	23
Grade 1	2
Grade 2	3
Grade 3	2

**Table 4:** Comparison of observed changes in rugae with the stages of body decomposition of cadavers in storage

Body Decomposition	Rugae Changes	Cadavers
Stage II	Grade 0	8
Stage III	Grade 0	15
	Grade 1	2
	Grade 2	1
Stage IV	Grade 2	2
	Grade 3	2

sition changes in their palatal rugae were in Stage III body decomposition. Of the cadavers with Grade 2 decomposition changes in their palatal rugae, one cadaver was in Stage III and two cadavers were in Stage IV body decomposition respectively. Two cadavers with Grade 3 decomposition changes in their palatal rugae were in Stage IV body decomposition (Table 4).

## DISCUSSION

Although there are many studies<sup>2, 4-8</sup> regarding identification of human remains using the dentition, literature reports of usage of palatal rugae for identification purposes are scarce. This study was planned to evaluate the retention of palatal rugae morphology under conditions simulating those found in mass disasters and to utilize this anatomical landmark for identification in such situations.

Palatal rugae were normal in 93% of the subjects sustaining pan facial third degree burns due to accidental fire. No changes were observed in the colour or surface anatomy in the palatal rugae of 77% of the human cadavers in storage. It is evident from this study that rugae are not markedly affected in survivors by the intensity of the fire and highlight the ability of palatal rugae to resist decomposition

changes for up to seven days after death under ideal conditions of storage in mortuary.

This study had its limitations in not considering the cause of death that might influence the rate of decomposition in cadavers and the variations of inter-investigator and intra-investigator assessments in grading the clinical condition of the palatal rugae of the subjects of the study group. The grading systems proposed need further testing. The effect of dentures influencing thermal changes on the palatal rugae of subjects involved in accidental fire also needs to be studied.

Comparisons of alterations in the palatal rugae with the generalized body conditions of incineration and decomposition of subjects of this study group provide an insight to the extent of possible palatal changes in real forensic situations. However further studies involving large number of individuals and extended periods after death in real forensic situations immediately after mass disasters are needed to substantiate the findings of this study and verify the usefulness of palatal rugae as a tool for forensic identification in such situations.

## REFERENCES

1. Philips ES. Introduction to forensic science. *Dent Clin North Am* 2001;45:217-28.
2. Sweet D, Di Zinno JA. Personal identification through dental evidence: Tooth fragments to DNA. *J Calif Dent Assoc* 1996;24:35-42.
3. Morlang WM. Forensic dentistry. *Aviat Space Environ Med* 1982;53:27-34.
4. Muhlemann HR, Steiner E, Brandestini M. Identification of mass disaster victims. The Swiss identification system. *J Forensic Sci* 1979;24:173-81.
5. Nambiar P, Jalil N, Singh B. The dental identification of victims of an aircraft accident in Malaysia. *Int Dent J* 1997;47:9-15.
6. Anderson L, Juhl M, Solheim T, Burrman H. Odontological identification of fire victims: potentialities and limitations. *Int J Legal Med* 1995;107:229-34.
7. Gillespe TH, Brannon RB, Gowdner JD, Grayson FW. Dental identification of remains from 23 October 1983 bombing of US marine headquarters, Beirut, Lebanon. *Military Med* 1985;150:635-9.
8. Moody GH, Busuttill A. Identification in the Lockerbie air disaster. *Am J Forensic Med Pathol* 1994;15:63-9.
9. English WR, Robinson SF, Summitt JB, Oesterle LJ, Brannon RB, Morlang WM. Individuality of human palatal rugae. *J Forensic Sci* 1988;33:718-26.
10. Harrison A. The palatal rugae in man. *Proc Acad Nat Soc* 1889;6:245.
11. Thomas CJ, Kotze T. The palatal ruga pattern: a new classification. *J Dent Assoc S Afr* 1983;38:153-7.
12. Kapali S, Townsend G, Richards L and Parish T. Palatal rugal patterns in Australian Aborigines and Caucasians. *Aust Dent J* 1997; 42(2):129-133.
13. Wallace AB. In: Russel RCG, Williams NS, Bulstrode CJK. Eds. *Bailey and Love's Short Practice of Surgery*. 23rd edn. London:Arnold, 2000:189.
14. Clark MA, Worrell MB, Pless JE. Postmortem changes in soft tissues. In: Haglund WD, Sorg MA. Eds. *Forensic Taphonomy. The postmortem fate of human remains*. Boston: CRC Press, 1997:151-64.

### **Address for correspondence:**

*K.S.Limson  
157 Gangawar Lane  
Oppanakara Street  
Coimbatore-641001  
Tamilnadu, INDIA  
Tel: +91 422 2399541  
Email: lovelimson@yahoo.co.in*