

Semi-automatic forensic approach using mandibular midline lingual structures as fingerprint: a pilot study

.....
 Eman Shaheen¹
 Bassant Mowafy²
 Constantinus Politis¹
 Reinhilde Jacobs¹

¹ OMFS IMPATH research group, Department of Imaging and Pathology, Faculty of Medicine, KU Leuven and Oral and Maxillofacial Surgery, University Hospitals Leuven, Leuven, Belgium

² Oral and Maxillofacial Radiology, Faculty of Dentistry, Mansoura University, Mansoura, Egypt

.....
Corresponding author:
eman.shaheen@uzleuven.be

Disclosures of Conflicts of Interest:
 none declared

KEYWORDS

.....
forensic identification, finger print, mandibular lingual canals, forensic odontology, victim identification

.....
 J Forensic Odontostomatol 2017. Dec;
 (35): 35-41
 ISSN :2219-6749

ABSTRACT

Background: Previous research proposed the use of the mandibular midline neurovascular canal structures as a forensic finger print. In their observer study, an average correct identification of 95% was reached which triggered this study.

Aim: To present a semi-automatic computer recognition approach to replace the observers and to validate the accuracy of this newly proposed method.

Materials and methods: Imaging data from Computer Tomography (CT) and Cone Beam Computer Tomography (CBCT) of mandibles scanned at two different moments were collected to simulate an AM and PM situation where the first scan presented AM and the second scan was used to simulate PM. Ten cases with 20 scans were used to build a classifier which relies on voxel based matching and results with classification into one of two groups: "Unmatched" and "Matched". This protocol was then tested using five other scans out of the database. Unpaired t-testing was applied and accuracy of the computerized approach was determined.

Results: A significant difference was found between the "Unmatched" and "Matched" classes with means of 0.41 and 0.86 respectively. Furthermore, the testing phase showed an accuracy of 100%.

Conclusion: The validation of this method pushes this protocol further to a fully automatic identification procedure for victim identification based on the mandibular midline canals structures only in cases with available AM and PM CBCT/CT data.

INTRODUCTION

Teeth have been widely used for forensic victim identification. Since the mandible is the strongest bone of the skeleton of the face, it is often preserved after death¹ which raises the interest in the potential value of mandibular bony fragments as identification methodology. The mandible contains many accessory foramina and canals, mainly on the lingual side, with anatomical variation among individuals.^{2,3} The mandibular midline foramina are different in number, morphology, size and intraosseous canal structures.^{4,5} These significant distinctions make these midline structures unique for a particular individual.⁶

Recent developments in dentomaxillofacial radiology such as Computer Tomography (CT) and Cone Beam Computer Tomography (CBCT) with high quality images and low dose aided in the extensive use of these technologies in the fields of dentistry and maxillofacial surgery. Moreover, some countries participating in war let the officers take a CBCT prior to departure to be used as an identification tool in case of death.⁷

Combining these factors, previous research⁷ was triggered in which the mandibular midline neurovascular canal structures was investigated as a forensic fingerprint. In their research, observers evaluated CBCT data of ante-mortem (AM) and post-mortem (PM) showing an average score of 95% correct identification.

The aim of this study was to present a semi-automatic computer recognition protocol to identify PM cases by comparing their mandibular midline canal structures to AM cases and to validate the accuracy of this approach.

MATERIALS AND METHODS

Ethical approval

Ethical approval was obtained from the Ethical Review Board of the University Hospitals Leuven (S57587). No informed consent was required for this retrospective study as no patients' identifiable data was disclosed.

Patient selection

CBCT/CT scans of 13 human mandibles were selected retrospectively from patients referred to the Dentomaxillofacial Radiology Centre (University Hospitals Leuven, Leuven, Belgium) with 10 cases having 2 scans with adequate image quality (no patient movement, no poor quality, etc.), no fracture in the lower jaw and no pathological lesions in the interforaminal region of the mandible. The mean difference between the 2 scans was 1.5 years. These 20 scans served as training data. Two of the 10 cases had a third scan at least one year later to the second scan and the last 3 cases had only 1 scan. These 5 scans were used as testing subjects to the protocol. The imaging modalities for these 25 scans were 4 CBCTs and one CT: 1. Accuitomo 170 (Morita, Kyoto, Japan), 2. Scanora 3D (Soredex, Tuusula, Finland), 3. ProMax (Planmeca OY, Helsinki, Finland), 4. NewTom VGi evo (QR s.r.l, Italy) and 5. Spiral CT scanner (Siemens Somatom

Definition Flash; Siemens AG, Erlangen, Germany)

Matching protocol of AM and PM data

The general procedure to identify a PM to its corresponding AM is based on the assumption of having a database of AM mandibles then apply the protocol of the PM in question to all AM in the database until a correct classification is reached. The 2 available classes are: "Matched" and "Unmatched". The "Matched" class is when a correct identification is reached, while the "Unmatched" class is when no correct identification is reached. The general procedure of the matching protocol is explained as follows:

1. Region of interest (ROI) identification: which is the extraction of the mandibular midline canal region in three dimension (3D) as a volume.
2. Voxel based registration: apply a rigid voxel based registration procedure between the AM and PM to calculate a metric value.
3. Classification: measure the difference between the obtained metric value and the mean of each class (Matched vs Unmatched). The closer (lower) the difference value is to a class then it means that the AM belongs to that class.

Building the classifier

The 10 cases with 2 scans were used to build the classifier. The first scan of each case was considered the AM situation while the second scan was used to simulate the PM. Each PM was compared to each AM resulting into 100 comparisons. The target was to be able to group the correct matched scans (n=10) into a group totally separated from the rest of the cases that should not match (n=90).

The DICOM images of each scan were then imported into the Amira software (FEI, USA) where all the steps were implemented as follows:

1. Each ROI was identified by selecting the Pogonion point (Pog), i.e. the most anterior point on the mandibular. A window of width 9 mm with the Pog as the middle point and height starting from of the Menton (Me) which is the lowest point on the lower border of the mandibular symphysis, up to the Infradentale point (Id) which is the most superior anterior point on the mandibular alveolar process between the central incisors. Figure 1 shows an example of ROI identification process.

2. Each ROI was then resampled to have isotropic voxel size equivalent to the highest resolution. For example, if the voxel size of the case was $0.2 \times 0.2 \times 1 \text{ mm}$, it is then resampled to $0.2 \times 0.2 \times 0.2 \text{ mm}$.
3. Each PM was registered to each AM via rigid voxel based registration with mutual information and a corresponding metric value was then recorded.⁸⁻¹⁰ The idea behind the volumetric matching algorithm is trying to align 2 objects based on information theory and similarities between these 2 objects. This metric has no unit of measurement and is closer to zero when the objects are not similar while higher values are found (closer to 1) when these objects are more similar to each other.
4. Each correct AM and corresponding PM metric values were grouped under "Matched" class ($n=10$) while all other pairs were grouped under "Unmatched" class ($n=90$).
5. The mean value of each class was calculated and used for the classification step to identify the PM belongs to which class. Figure 2 shows an example of a correctly "Matched" case and another correctly "Unmatched" case.

Testing and validation

After the classifier was built, the testing phase started. Two cases from the 10 subjects had a later scan of CBCT at least one year after the second scan. These were used to identify matched cases while the other 3 cases with single scan were used to identify unmatched cases. The matching protocol was applied to these 5 scans that served as testing subjects.

Statistical analysis

Data was analysed using the statistical software package MedCalc (Version 16.4.2, MedCalc Software, Ostend, Belgium). In a first step, the

Figure 1: Example of ROI identification.

- (A) The whole mandible with the ROI surrounding.
- (B) Frontal view of the ROI after extraction.
- (C) Lateral view of the ROI after extraction.
- (D) Midsagittal cut slice of the ROI showing the midline lingual structures.

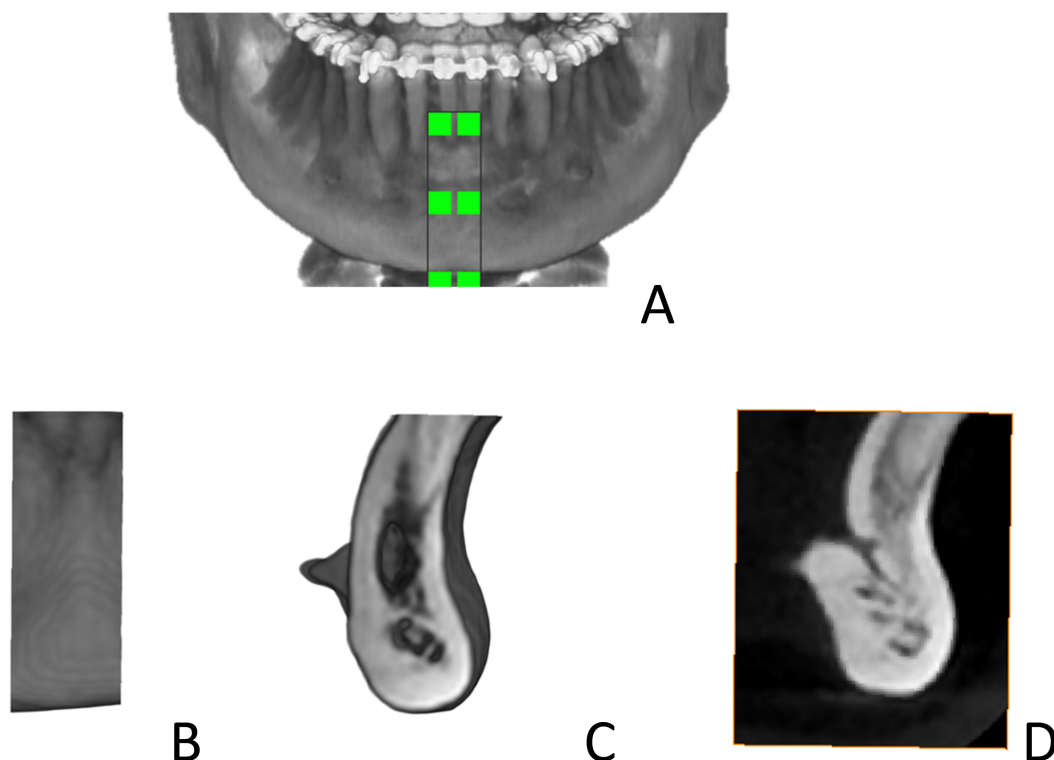


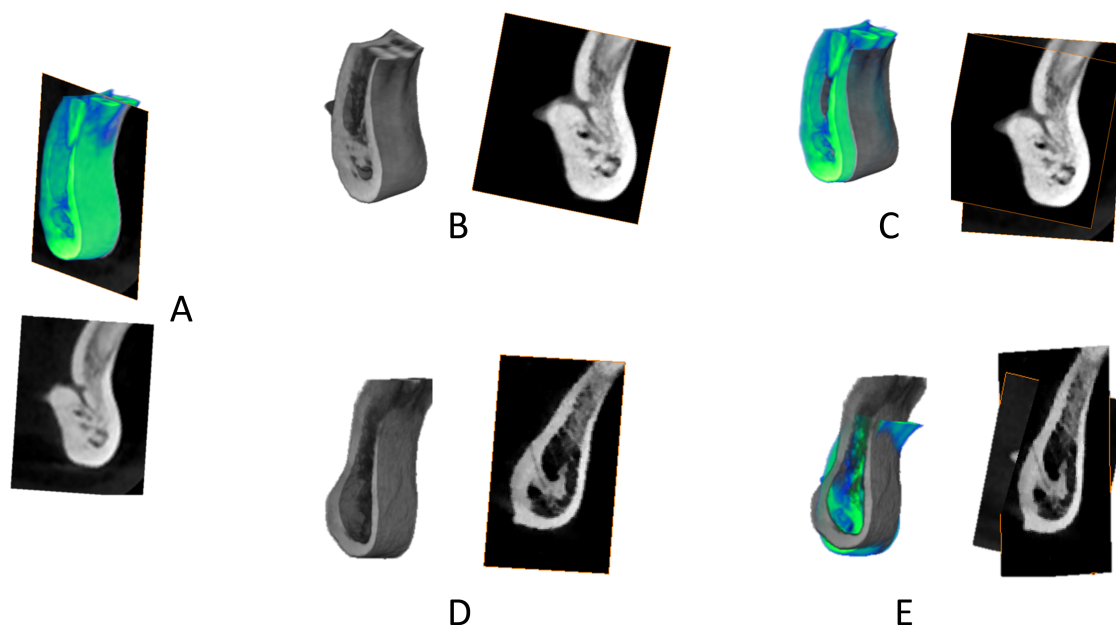
Figure 2: Example of classification (step 3 of matching protocol) with every ROI the midsagittal cut slice is shown.

(A) ROI of AM case shown in Figure 1.

(B) ROI of corresponding PM case.

(C) PM (B) to AM (A) registration showing perfect matching (metric value = 1).

(D) ROI of another PM that does not match. (E) PM (D) to AM (A) registration showing no matching (metric value = 0.4)



Shapiro-Wilk test was performed to validate the normality assumption. For the “Matched” and “Unmatched” groups, the means, standard deviations, the 95% confidence interval of the mean and standard error of the means were calculated as the means were used for classification purposes. The unpaired t-test was applied to compare between the two classes. Statistical significance was set at a P-value ≤ 0.05. For the testing procedure, the accuracy, specificity and sensitivity were calculated.

Classification results

The Shapiro-Walk testing proved normality distribution of the measurements. Table 1 shows the descriptive results of the “Unmatched” and “Matched” groups and Figure 3 shows the bar plot of these groups. Statistical significant difference (P<0.0001) was found between the two classes with mean of metric values of 0.41 and 0.86 corresponding to “Unmatched” and “Matched” respectively.

Table 1: Descriptive results of the classes: “Unmatched” and “Matched”

	Sample size (n)	Mean	Standard Deviation	95% CI for the mean	Standard error of the mean	Unmatched vs Matched
Unmatched	90	0,41	0,11	0,3903 to 0,4373	0,01	P < 0,0001
Matched	10	0,86	0,15	0,7540 to 0,9700	0,05	

Fig.3: Bar plot of the two classes: “Unmatched” and “Matched”

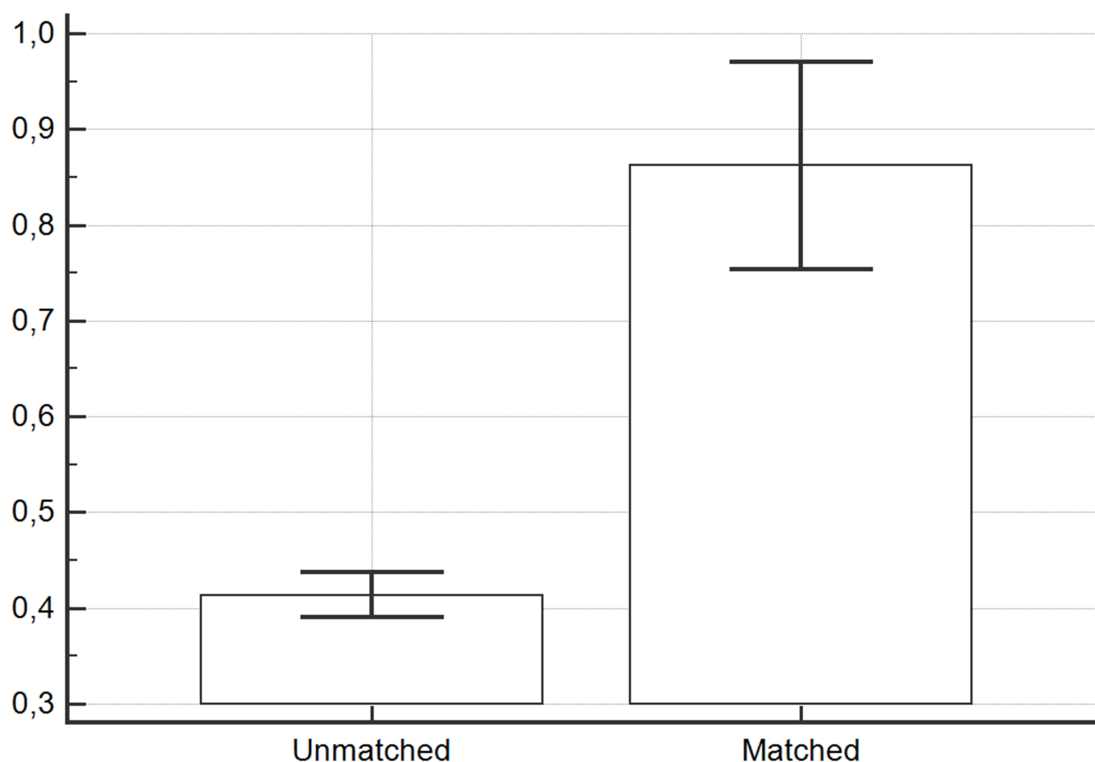


Table 2: Classification results of the 5 testing cases versus the 10 AM cases in the database.

	P1	P2	P3	P4	P5	P6	P7	P8	P9	P10
PTest1	I	o	o	o	o	o	o	o	o	o
PTest2	o	I	o	o	o	o	o	o	o	o
PTest3	o	o	o	o	o	o	o	o	o	o
PTest4	o	o	o	o	o	o	o	o	o	o
PTest5	o	o	o	o	o	o	o	o	o	o

Testing results

Table 2 presents the classification results of the 5 testing cases when compared to the 10 AM cases in the database. It has to be noted that PTest1 was the third scan of P1 and the PTest2 was the third scan of P2. Therefore, based on this classification, the accuracy was found to be 100%, sensitivity and specificity were also 100%.

DISCUSSION

In this paper we presented a semi-automatic protocol to identify PM cases by comparing their mandibular midline canal structures to AM cases. The first aim was to build a classifier which was done based on 10 subjects. The results showed that the classes “Unmatched” and “Matched” were significantly different. The means, standard

deviations and 95% confidence intervals of the mean revealed no overlap between the two classes (Table 1, Figure 3). However, as with any classifier, outliers could be found where 3 out of the 100 matches were misclassified indicating an accuracy of 97%.

The second aim was to validate and test the accuracy of the classifier which was done using 5 scans. The testing phase revealed an accuracy of 100%. An example of a matching procedure was shown in Figure 2 with correct matching into the "Matched" class (Figure 2C) with metric value of 1 while the correct classification in Figure 2E into the "Unmatched" class was with metric value of 0.4.

Based on these results, the proposition that the mandibular midline canal structures are indeed unique and can be used in identification of victims when AM and PM CBCT/CT data are made available. Different factors would affect the accuracy of this proposed protocol such as imaging, ROI selection and sample size. As mentioned previously, 4 different CBCT systems and one CT were used for the building and testing phases. The use of different systems didn't affect the results and this could be explained by the use of voxel based registration with mutual information as the method relies on similarities between volumetric information. This method overcomes the errors that could rise if segmentation and surface/point based registration were used due to the difficulties of accurate segmentation from CBCT images¹¹ and the lower accuracy of surface or point based registration.¹² Another factor in imaging would be the voxel size, the smaller the voxel size, the better the resolution and thus more accurate results. In this study, most voxels were not isotropic and this would affect the registration, therefore, the resampling step was added to have isotropic voxel sizes. The largest voxel size in the z direction (slice thickness) was 1mm. Larger

voxel sizes were not tested. Metal and filling artifacts¹³ didn't play a role in this study as the region of interest is quiet far from such artefacts. Exceptional cases would be cases with mandibular trauma but they were excluded from this study or patients who underwent genioplasty, these also would be excluded.

The protocol was called semi-automatic because of the first step of ROI selection which was done manually. The cephalometric points identification was an attempt to improve this manual step towards automation which would require from the user to identify only 3 points (Pog, Me and Id). However, cephalometric point identification is prone to user error up to 2mm.^{11,14,15} Nevertheless, the use of a bounding box to extract the ROI based on these points and with a window width of 9 mm was selected to overcome these possible errors. Then all the other steps can be easily automated with no user interference even the ROI selection step could be automated as shown by Codari et al.¹¹

It is true that this study was a proof of concept built with only 10 matching cases and tested against 5 other scans, but the promising outcome of the automation method suggests the use of this procedure to build a larger database. The proposed method would be a useful tool to filter out cases to facilitate victim identification. Nevertheless, more tests are needed on larger datasets to further verify the accuracy of this procedure.

CONCLUSIONS

The mandibular midline canal structures may be used to facilitate victim identification when AM and PM CBCT/CT mandibular data are present. The outcome of the current research may serve as a basis for further studies on automated victim identification by means of this patient-specific anatomic structure as well as other potentially unique anatomical landmarks.

REFERENCES

1. Pillai TJ, Devi TS DC. Studies on human mandibles. *IOSR J Dent Med Sci*. 2014;13(1):8-15.
2. Sutton RN. The practical significance of mandibular accessory foramina. *Aust Dent J*. Blackwell Publishing Ltd; 1974;19(3):167-73.
3. Murlimanju BV, Prakash KG, Samiullah D, Prabhu LV, Pai MM, Vadgaonkar R, Rai R. Accessory neurovascular foramina on the lingual surface of mandible: incidence, topography, and clinical implications. *Indian J Dent Res. Medknow Publications and Media Pvt. Ltd.*; 2012;23(3):433.
4. Vandewalle G, Liang X, Jacobs R, Lambrichts I. Macroanatomic and radiologic characteristics of the superior genial spinal foramen and its bony canal. *Int J Oral Maxillofac Implants*. 2006;21:581-6.
5. Liang X, Jacobs R, Lambrichts I, Vandewalle G, Van Oostveldt D, Schepers E, Adriaensens P, Gelan

- J. Microanatomical and histological assessment of the content of superior genial spinal foramen and its bony canal. *Dentomaxillofacial Radiol.* 2005;34(6):362-8.
6. Ennis LM. Roentgenographic variations of the maxillary sinus and the nutrient canals of the maxilla and the mandible. *Int J Orthod Oral Surg.* 1937;23(2):173-93.
 7. Elmowafey B, Vande Casteele E, Politis C, Jacobs R. Can the mandibular lingual canals be used as a forensic fingerprint? 2015;33(2):26-35.
 8. Viola P, Chao A. Multiple sensor image alignment by maximization of mutual information. In: Massachusetts Institute of Technology and ALPHATECH, Inc. 1995.
 9. Collignon A, Maes F, Delaere D, Vandermeulen D, Suetens P, Marchal G. Automated multi-modality image registration based on information theory. 14th Int Conf Inf Process Med Imaging. 1995;263-74.
 10. Pluim JPW, Maintz JBA, Viergever MA. Mutual information based registration of medical images: a survey. *IEEE Trans Med Imaging.* 2003;22(8):986-1004.
 11. Codari M, Caffini M, Tartaglia GM, Sforza C, Baselli G. Computer-aided cephalometric landmark annotation for CBCT data. *Int J Comput Assist Radiol Surg.* 2017;12(1):113-21.
 12. Almukhtar A, Ju X, Khambay B, McDonald J, Ayoub A. Comparison of the accuracy of voxel based registration and surface based registration for 3D assessment of surgical change following orthognathic surgery. *PLoS One.* 2014;9(4):1-6.
 13. Codari M, de Faria Vasconcelos K, Ferreira Pinheiro Nicolielo L, Haiter Neto F, Jacobs R. Quantitative evaluation of metal artifacts using different CBCT devices, high-density materials and field of views. *Clin Oral Implants Res.* 2017;1-6.
 14. Pucciarelli V, Codari M, Girardi A, Giustinetti C, Martino G, Caffini M, Baselli G, Sforza C. Evaluation of accuracy and reproducibility in manual point picking during 3D cephalometry on CBCT data. *Ital J Anat Embryol.* 2015;120(1):54321.
 15. Pittayapat P, Limchaichana-Bolstad N, Willems G, Jacobs R. Three-dimensional cephalometric analysis in orthodontics: A systematic review. *Orthod Craniofacial Res.* 2014;17(2):69-91.