

## CASE REPORT

# Taurodontism and its forensic value: a case report

Mário Marques Fernandes<sup>1,2</sup>,  
Rhonan Ferreira Silva<sup>3</sup>,  
Tessa De Lucena Botelho<sup>4</sup>,  
Rachel Lima Ribeiro Tinoco<sup>5</sup>,  
Vania Fontanella<sup>6</sup>,  
Rogério Nogueira de Oliveira<sup>2</sup>.

<sup>1</sup>Biomedical Service of the Public Ministry of the State of Rio Grande do Sul, Porto Alegre/RS, Brazil.

<sup>2</sup>Department of Social Dentistry, Dental School of University of São Paulo, São Paulo/SP, Brazil.

<sup>3</sup>Dental School of Federal University of Goiás, Goiânia/GO, Brazil.

<sup>4</sup>Dental School, Campus Flamboyant, Paulista University, Goiânia/GO, Brazil.

<sup>5</sup>Salgado de Oliveira University, Niterói/RJ, Brazil.

<sup>6</sup>Dental School, Federal University of Rio Grande do Sul, Porto Alegre/RS, Brazil

**Corresponding author:**  
vaniafont@ufrgs.br

The authors declare that they have no conflict of interest.

## KEYWORDS

Diagnostic imaging  
Tooth abnormalities  
Expert testimony  
Forensic dentistry  
Patient identification systems

**ABSTRACT**

Taurodontism is an anomaly that affects posterior teeth, vertically increasing the size of the pulp chamber, mimicking the shape of bovine teeth, being only evidenced in diagnostic images. This report describes a case of taurodontism in a mandibular second molar, highlighting the forensic importance of this dental anomaly with relevant potential for human identification, not only for its morphological aspect but also for its relatively low frequency in mandibular second molars. In the case under study, the individual did not have any restored teeth. Thus, the set of diverse imaging modalities is fundamental to identify the anatomy of teeth and roots, the only information that could be used in a hypothetical identification situation, assigning to this anomaly an exceptional relevance as a potential characteristic for positive identification.

**INTRODUCTION**

Tooth abnormalities are disorders that affect permanent or deciduous teeth due to inherited, congenital or acquired factors. Failures in development of the Hertwig's epithelial root sheath cause root anomalies, which may only be observed on imaging examinations.<sup>1,2</sup>

The term taurodontism was proposed to describe the vertical increase in pulp chamber size, mimicking the shape of bovine teeth.<sup>3</sup> This anomaly may be classified as hypo, meso or hypertaurodontism, according to the level of apical displacement of the pulp chamber floor.<sup>4</sup>

This developmental disorder may be associated with syndromes.<sup>5,7</sup> A prevalence of 60% was observed in Brazilian individuals with Down's syndrome,<sup>6</sup> but it also occurs in non-syndrome individuals.<sup>8-10</sup> Moreover, it is seen in individuals presenting other tooth abnormalities, such as dental agenesis.<sup>11-12</sup> Its prevalence varies according to the study population, without gender predilection, affecting molars and premolars in both dentitions, involving one or more teeth in the same individual (Table 1).<sup>13-23</sup> Most cases are classified as hypotaurodontism (75%), while hypertaurodontism is much less frequent (6%).<sup>16</sup>

From the standpoint of forensic investigations, taurodontism is a valuable tooth characteristic for human identification. In Forensic Dentistry the combination of specific dental characteristics of an individual allows differentiation from others when identity determination is necessary, such as in mass disasters.<sup>24</sup> Therefore, this paper reports a case of taurodontism of the mandibular second molar, highlighting its forensic relevance.

**Table 1:** Prevalence of taurodontism in recent studies in different populations.

| Study                                       | Population   | N    | Type of image | Teeth analyzed          | Prevalence (%) | 2LM*   |
|---|--------------|------|---------------|-------------------------|----------------|--------|
| Porto et al. (2009) <sup>21</sup>           | Brazilian    | 1300 | PAN/<br>FMS   | All molars              | 5.54           | 22/108 |
| Bürklein et al. (2011) <sup>14</sup>        | German       | 800  | FMS           | All molars              | 2.25           | 8/30   |
| Afify et al. (2012) <sup>15</sup>           | Saudi Arabia | 878  | PAN           | Posterior teeth         | 0.01           | n/a    |
| Patil et al. (2013) <sup>16</sup>           | Indian       | 4143 | PAN           | Posterior teeth         | 0.41           | 6/32   |
| Gupta, Saxena (2013) <sup>20</sup>          | Indian       | 1360 | FMS           | All molars              | 2.50           | 32/118 |
| Çolak et al. (2013) <sup>19</sup>           | Turkish      | 6912 | PAN/<br>FMS   | Posterior teeth         | 0.26           | 16/46  |
| Shokri et al. (2014) <sup>18</sup>          | Iranian      | 1649 | PAN           | All molars              | 3.34           | 42/228 |
| Gonçalves Filho et al. (2014) <sup>22</sup> | Brazilian    | 503  | PAN           | Posterior teeth         | 27.19          | n/a    |
| Puttalingaiah et al. (2014) <sup>13</sup>   | Indian       | 946  | PAN           | First mandibular molars | 17.30          | n/a    |
| Bharti et al. (2015) <sup>17</sup>          | Indian       | 1000 | FMS           | All molars              | 2.80           | n/a    |
| Pedreira et al. (2016) <sup>23</sup>        | Brazilian    | 562  | PAN           | Posterior teeth         | 4.98           | 12/26  |

PAN: Panoramic radiography; FMS: Full mouth survey; 2LM: Second lower molar. \* Number of 2LM taurodont/number of taurodont teeth; n/a: not available.

## CASE REPORT

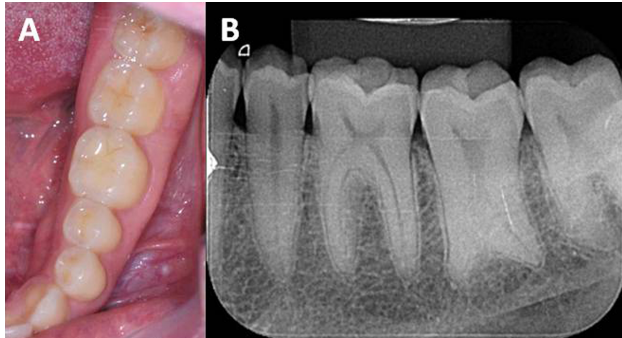
A 27 year-old man presenting with good general health was submitted to dental evaluation for job purposes (pre-hiring examination), also called administrative expert examination for entry in the public service staff. Besides clinical examination, previous images provided by the individual were also evaluated, including periapical and panoramic radiographs and cone beam computed tomography of the left posterior mandibular region.

Analysis of the images revealed hypertaurodontism of the mandibular left second molar, which presented crown with typical

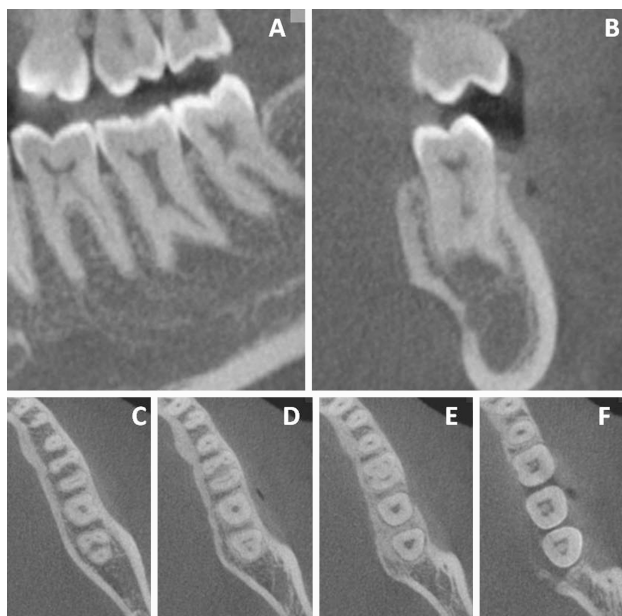
permanent mandibular second molar morphology and wide pulp chamber without nodules or obstructions (Fig. 1, Fig. 2). No other clinical or radiographic abnormalities were found that might preclude the job activity of the individual. Therefore, he was considered in good condition to take the job.

Consent was obtained from the individual, and the professional performing the expert examination prepared the material, assuring anonymity of the individual's data.

**Figure 1:** Mandibular left molars, highlighting the clinical aspect without anatomical abnormalities of the crown (A), and periapical radiographic image evidencing the particular aspect of hypertaurodontism on the mandibular left second molar (B).



**Figure 2:** Cone beam computed tomography: panoramic (A), parasagittal (B) and axial reconstructions (C to F).



## DISCUSSION

In Forensic Science, positive identification of an individual is achieved by the analysis of dental features in ante-mortem and post-mortem records, considering the combination of unique characteristics. This process is facilitated by the presence of variations that are not very frequent in the population, which serve as individualizing features. Within this context, taurodontism is a tooth abnormality with relevant potential for

human identification, not only for its morphological aspect but also due to its relatively low frequency in some populations. It is even more relevant when associated with parameters such as presence/absence of syndrome, type of taurodontism (hypo, meso or hypertaurodontism) and affected tooth.

Even though mathematical calculations are not routinely used in human identification, and considering that only an image exhibiting the anomaly for comparison would allow identification of an individual, the present case would require knowledge on the frequency of hypertaurodontism only in second molars, which should be added to other dental features observed in the identification examination. According to the literature reviewed, only four studies allowed calculation of the prevalence of taurodontism in mandibular second molars in different populations,<sup>18-21</sup> which would range from 0.13% to 1.2%.

The pre-hiring examination is within the classification of administrative expert examinations conducted in the public service, requested by an institutional authority usually related to human resources administration (of either Federal, State or Municipal governments).<sup>25,26</sup>

According to Brazilian regulation, the official dental expert is the only professional allowed to advise individuals about the occasional need of treatment, and refer them to rehabilitation if necessary. This highlights the function of health promotion, avoiding absenteeism of the newly hired individual for the provision of dental treatment.<sup>27</sup> In the present case, the individual did not require any treatment, since the teeth were healthy; however, he was informed about the taurodontism observed on radiographic images.

The second function of administrative expert examination is to record specific features that may be helpful in the occasional need of forensic dental identification. In the present case, the individual did not have any restored teeth. Therefore, the combination of several imaging modalities is fundamental to identify the anatomy of teeth and roots, the only information that might be used in a hypothetical identification situation, assigning to this anomaly an exceptional relevance as a potential characteristic for positive identification.

## REFERENCES

1. Dineshshankar J, Sivakumar M, Balasubramaniam AM, Kesavan G, Karthikeyan M, Prasad VS. Taurodontism. *J Pharm Bioallied Sci* 2014; 6: 13-15.
2. Luder HU. Malformations of the tooth root in humans. *Front Physiol* 2015; 6: 307. Available from: [www.frontiersin.org/articles/10.3389/fphys.2015.00307/full](http://www.frontiersin.org/articles/10.3389/fphys.2015.00307/full) [cited 10 May 2018].
3. Keith A. Problems relating to the teeth of the earlier forms of prehistoric man. *Proc R Soc Med* 1913; 6: 103-124.
4. Shaw JCM. Taurodont teeth in South African races. *J Anat* 1928; 62: 476-498.
5. Sekerci AE, Cantekin K, Aydinbelge M, Ucar FI. Prevalence of dental anomalies in the permanent dentition of children with Down syndrome. *J Dent Child* 2014; 81:78-83.
6. Moraes LC, Medici Filho E, Castilho JC de M, Moraes MEL de, Dotto PP, Dotto GN. Ocorrência de taurodontismo em indivíduos portadores de síndrome de Down. *Rev Inst Ciênc Saúde* 2004; 22: 317-322.
7. Krishnamoorthy S, Gopikrishna V. Endodontic management of a hypertaurodontic tooth associated with 48, XXYY syndrome: A review and case report. *J Conserv Dent* 2015; 18: 265-268.
8. Jamshidi D, Adl A, Sobhnamayan F, Bolurian M. Root canal treatment of a hypertaurodont mandibular second molar: a case report. *J Dent Res Dent Clin Dent Prospects* 2015; 9:57-59.
9. Nagaveni NB. An unusual occurrence of multiple dental anomalies in a single nonsyndromic patient: a case report. *Case Rep Dent* 2012; 2012: 426091. Available from: [www.hindawi.com/journals/crid/2012/426091/](http://www.hindawi.com/journals/crid/2012/426091/) [cited 10 May 2018].
10. Borges AH, Mamede-Neto I, Volpato LE, Pedro FL, Bueno MR, Estrela C. Using cone beam computed tomography images to diagnose multiple taurodontisms. *Gen Dent* 2014; 62: 20-22.
11. Gomes RR, da Fonseca JA, Paula LM, Faber J, Acevedo AC. Prevalence of hypodontia in orthodontic patients in Brasilia, Brazil. *Eur J Orthod* 2010; 32(3):302-306.
12. Gomes RR, Habckost CD, Junqueira LG, Leite AF, Figueiredo PT, Paula LM, Acevedo AC. Taurodontism in Brazilian patients with tooth agenesis and first and second-degree relatives: a case-control study. *Arch Oral Biol* 2012; 57: 1062-1069.
13. Puttalingaiah VD, Agarwal P, Miglani R, Gupta P, Sankaran A, Dube G. Assessing the association of taurodontism with numeric dentition anomalies in an adult central Indian population. *J Nat Sci Biol Med* 2014; 5: 429-433.
14. Bürklein S, Breuer D, Schäfer E. Prevalence of taurodont and pyramidal molars in a German population. *J Endod* 2011; 37: 158-162.
15. Afify AR, Zawawi KH. The prevalence of dental anomalies in the western region of Saudi Arabia. *ISRN Dent* 2012; 2012: 837270. Available from: [www.hindawi.com/journals/isrn/2012/837270/](http://www.hindawi.com/journals/isrn/2012/837270/) <http://www.hindawi.com/journals/crid/2012/426091/> [cited 10 May 2018].
16. Patil S, Doni B, Kaswan S, Rahman F. Prevalence of taurodontism in the North Indian population. *J Clin Exp Dent* 2013; 5: e179-182. Available from: [www.ncbi.nlm.nih.gov/pmc/articles/PMC3892237/](http://www.ncbi.nlm.nih.gov/pmc/articles/PMC3892237/) [cited 10 May 2018].
17. Bharti R, Chandra A, Tikku AP, Arya D. Prevalence of Taurodont molars in a North Indian population. *Indian J Dent* 2015; 6: 27-31.
18. Shokri A, Poorolajal J, Khajeh S, Faramarzi F, Kahnamouei HM. Prevalence of dental anomalies among 7- to 35-year-old people in Hamadan, Iran in 2012-2013 as observed using panoramic radiographs. *Imaging Sci Dent* 2014; 44: 7-13.
19. Çolak H, Tan E, Bayraktar Y, Hamidi MM, Çolak T. Taurodontism in a central anatolian population. *Dent Res J* 2013; 10: 260-263.
20. Gupta SK, Saxena P. Prevalence of taurodontism and its association with various oral conditions in an Indian population. *Oral Health Prev Dent* 2013; 11: 155-160.
21. Porto MT, Souza EC, Brücker MR. Prevalência de taurodontismo em pacientes da Faculdade de Odontologia da PUCRS. *Rev Ciênc Méd Biol* 2009; 8: 39-45.
22. Gonçalves-Filho AJ, Moda LB, Oliveira RP, Ribeiro AL, Pinheiro JJ, Alves-Junior SR. Prevalence of dental anomalies on panoramic radiographs in a population of the state of Pará, Brazil. *Indian J Dent Res* 2014; 25: 648-652.
23. Pedreira FRO, Carli ML, Pedreira RPG, Ramos OS, Pedreira MR, Robazza CRC, et al. Association between dental anomalies and malocclusion in Brazilian orthodontic patients. *J Oral Sci* 2016; 58: 75-81.
24. MacDonald-Jankowski DS. Taurodontism and the identification of a mass disaster victim. *Dent Update* 1993; 20(1):39.
25. Alcântara HR. Perícia médica judicial. 2nd ed. Rio de Janeiro. Guanabara Koogan; 2006.
26. Marques CTV. Perícia administrativa. In: Epiphânio EB, Vilela JPX. Perícias médicas: teoria e prática. Rio de Janeiro. Guanabara Koogan; 2009. p 203-217.
27. Conselho Federal de Odontologia. Resolução CFO 87, de 26 de maio de 2009. Normatiza a perícia e junta odontológica e dá outras providências. [Internet]. Available from: <http://transparenciacfo.org.br/ato-normativo/?id=1356> [Cited 2018 Mar 29];